

# ORTHO.GENT

ORTHOPEDIE & TRAUMATOLOGIE

## **Fracturen van de hand: kleine botjes, grote gevolgen**

**Dr. Ph. Verniers**

23-03-2019

There is a fracture we need  
to fix it

# Fracturen van de hand

---

- ▶ Algemeenheden in behandeling
- ▶ Conservatief
- ▶ Operatief
  
- ▶ # phalangen : volwassenen / kinderen
- ▶ # metacarpalen : waarop letten
- ▶ # handwortel beentjes : kliniek/+

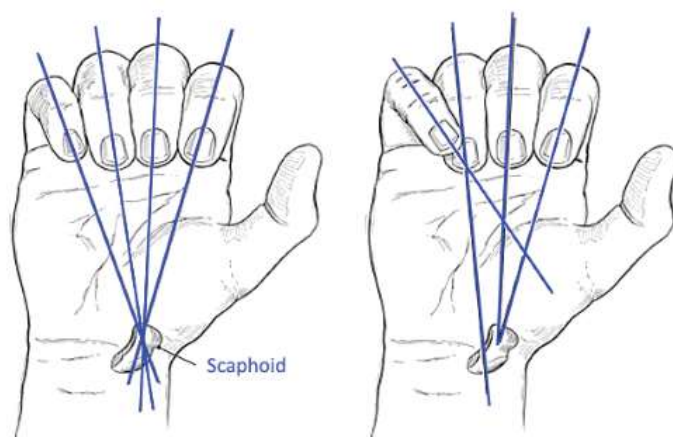
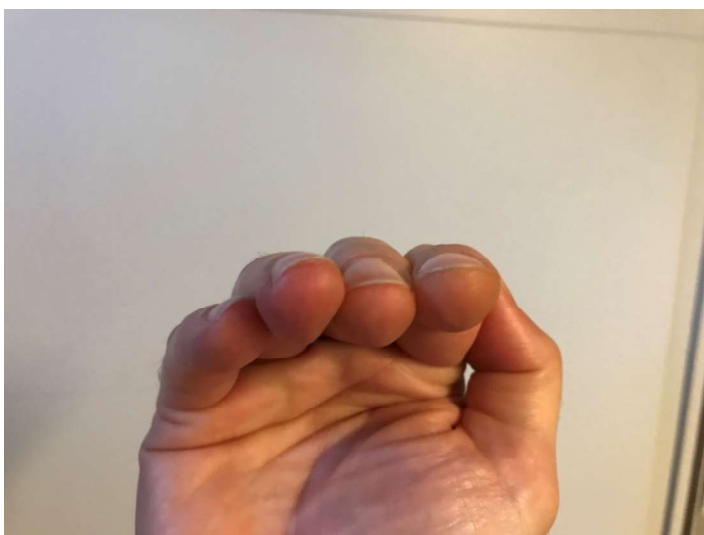# Behandeling

---

- ▶ Anatomische repositie / vroege mobilisatie
- ▶ Spiraalvormige # => rotatie
- ▶ Schuine of communitieve => verkorting
- ▶ Avulsie # basis phal. => uitgebreidere weke delen letsels

# Inspectie

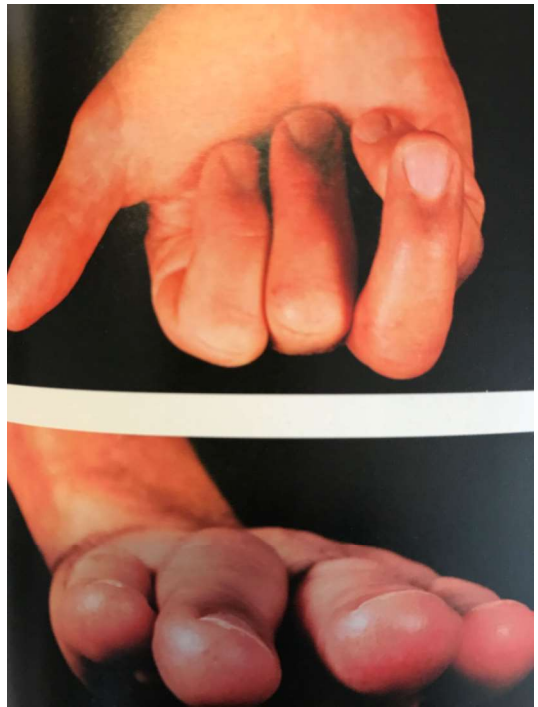
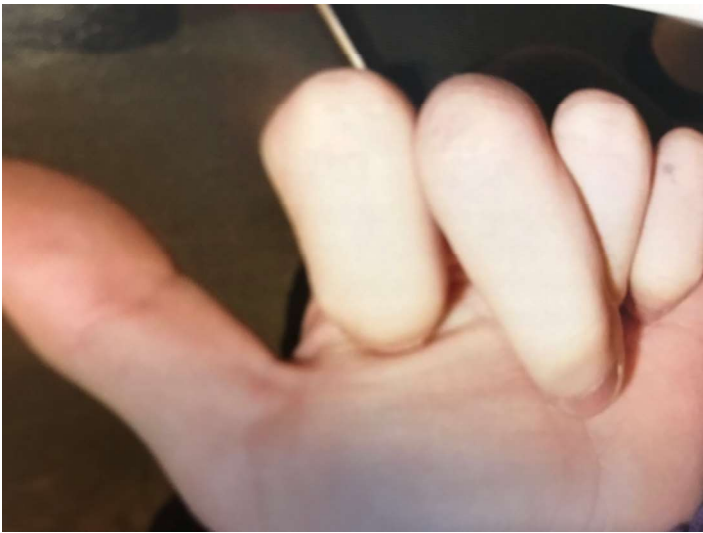
---



ORTHO.GENT

ORTHOPEDIE & TRAUMATOLOGIE





ORTHO.GENT

ORTHOPEDIE & TRAUMATOLOGIE

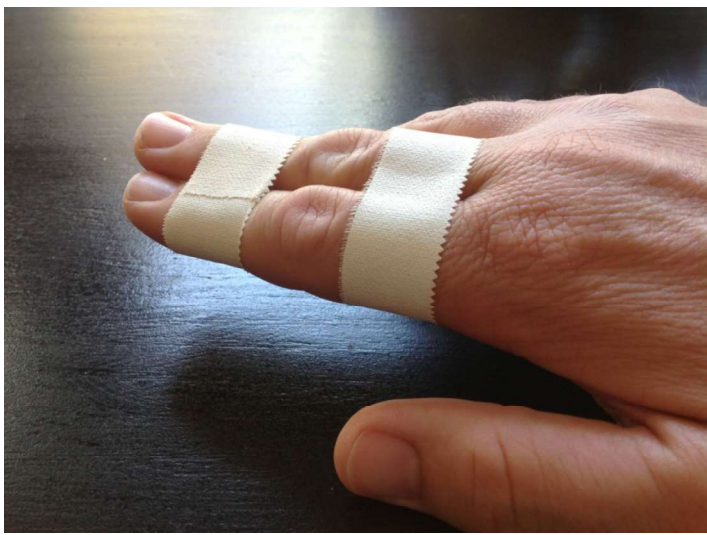

## Conservatieve behandeling

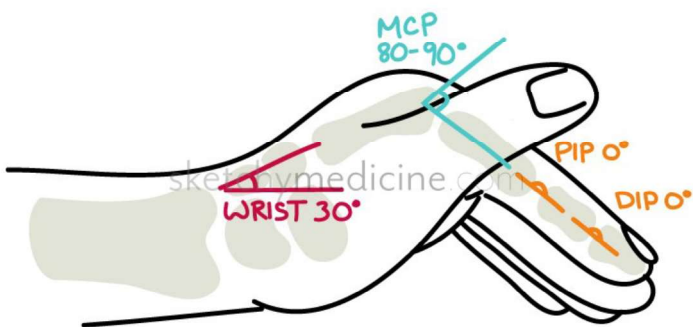
---

- ▶ Buddy taping
- ▶ Extra articulaire niet verplaatste
- ▶ Intrinsiek plus (safe hand)
- ▶ Verplaatste die stabiel zijn na reductie

▶ Buddy taping



▶ Safe hand positie

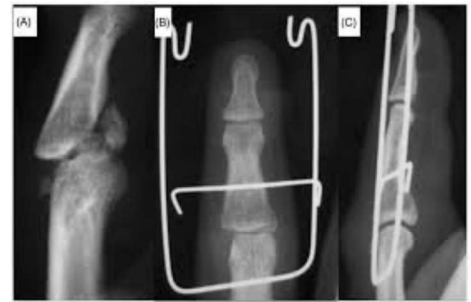
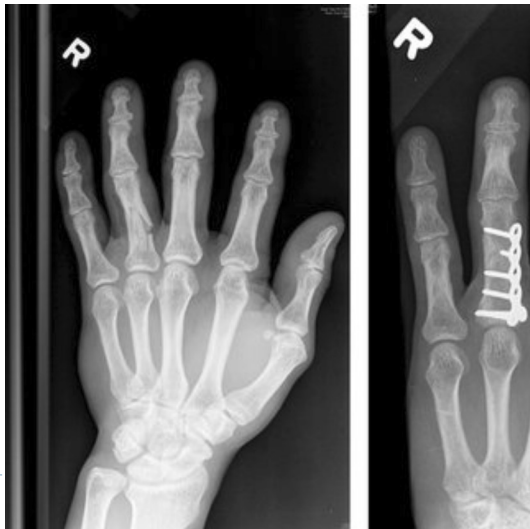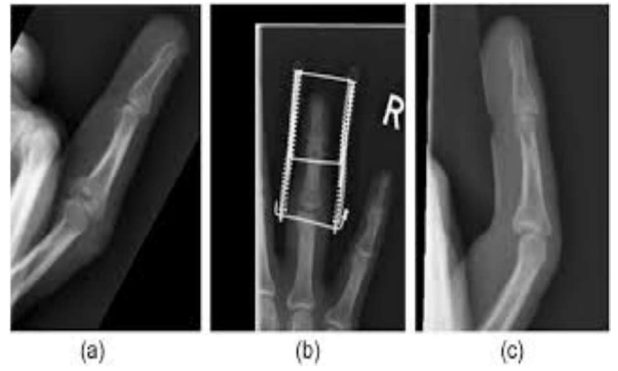
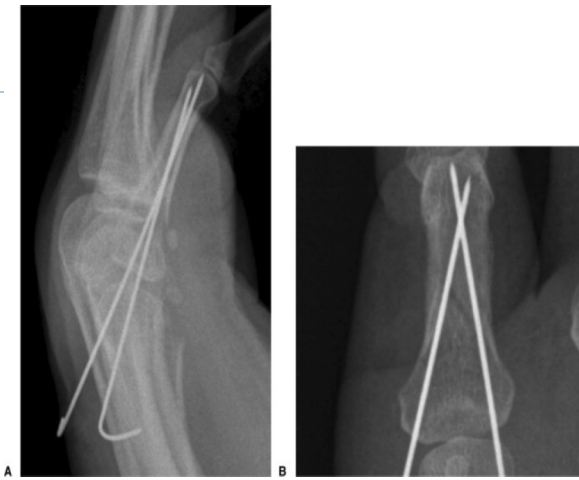


## Operatieve behandeling

---

- ▶ Intra –articulaire #
- ▶ Niet stabiele #
  - spiraalvormige
  - communitieve
  - schuine met verkorting
  - open # met weke delen laesie
- ▶ Gesloten reductie + pinning
- ▶ Open repositie + osteosynthese
- ▶ Dynamische tractie
- ▶ Ext fix





ORTHO.GENT

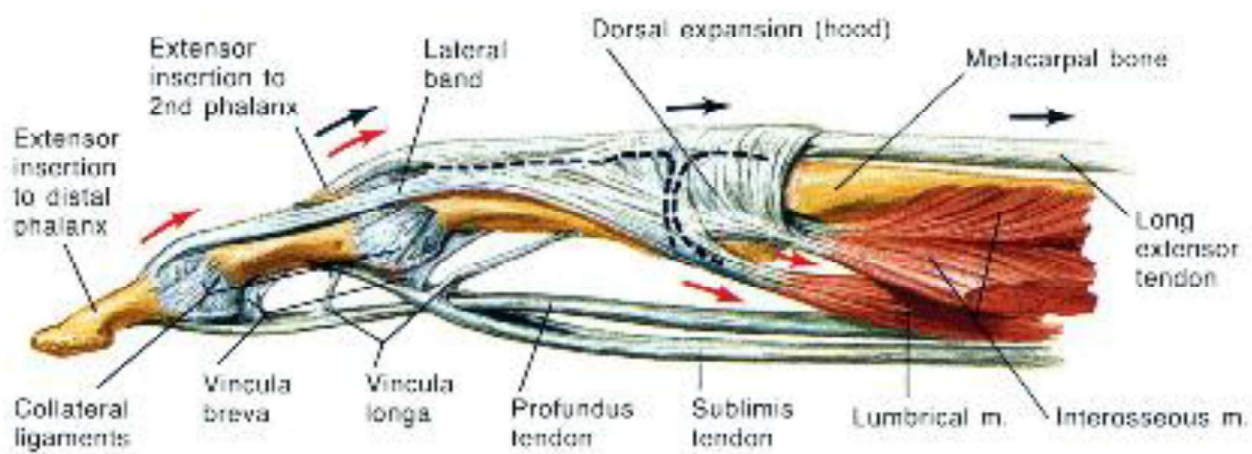
ORTHOPEDIE & TRAUMATOLOGIE



P3 / P2 / P1 #

---

**Lateral view**



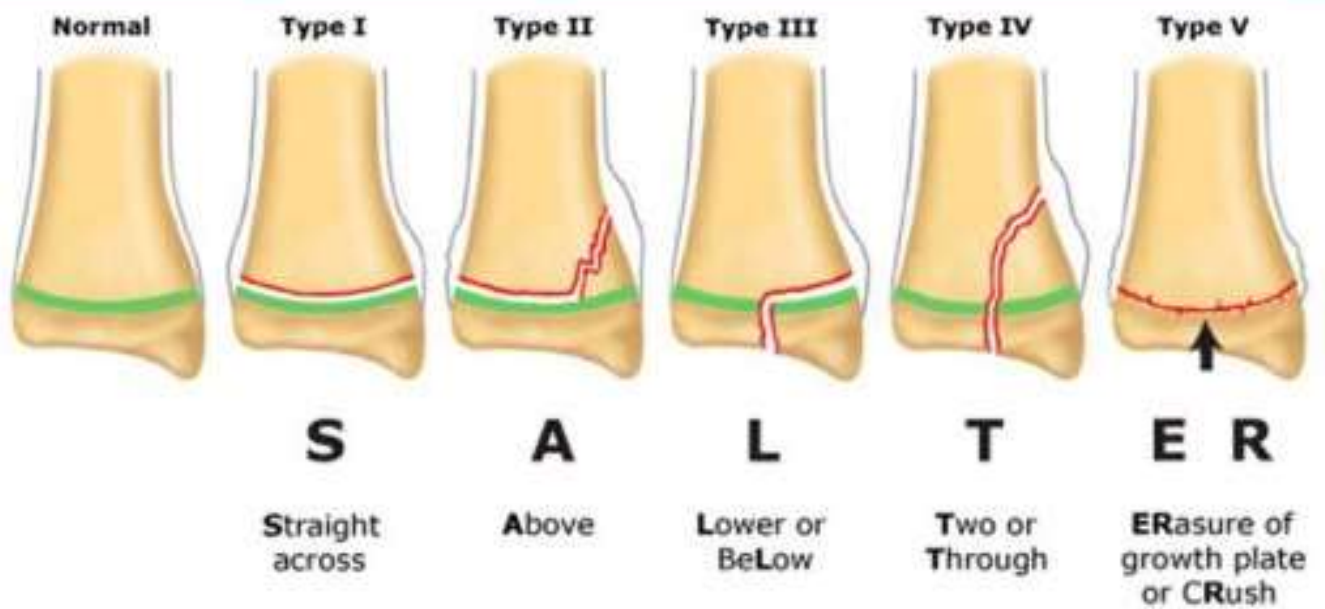
---

ORTHO.GENT

ORTHOPEDIE & TRAUMATOLOGIE

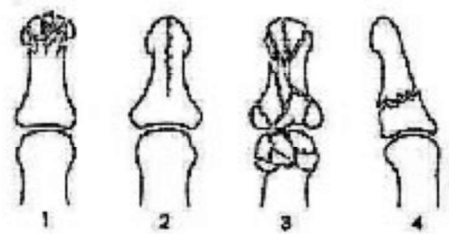


## Salter-Harris classification of physal fractures

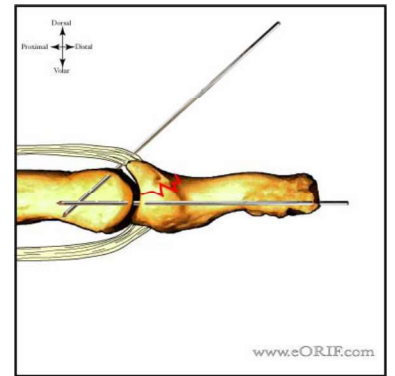
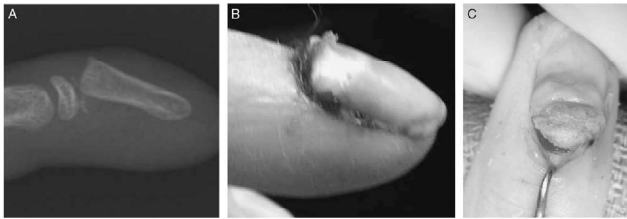
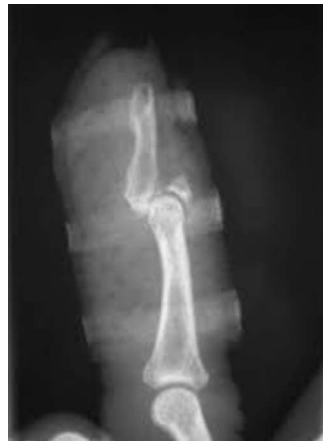

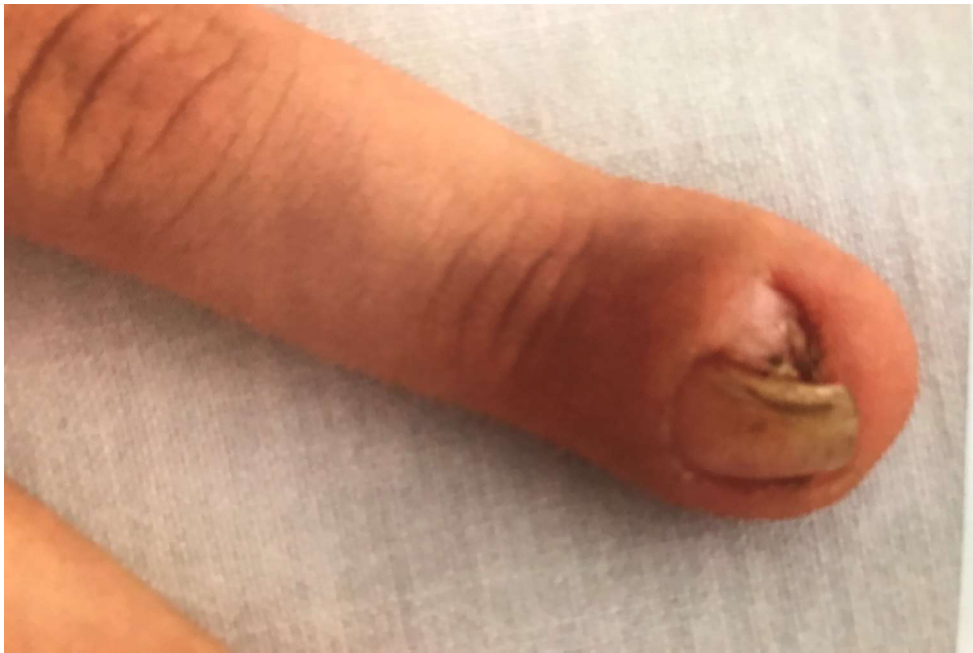# P3

- ▶ Tuft #
- ▶ Basis (mallet)



- ▶ Seymour kinderen





---

ORTHO.GENT

ORTHOPEDIE & TRAUMATOLOGIE

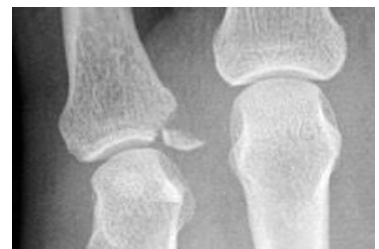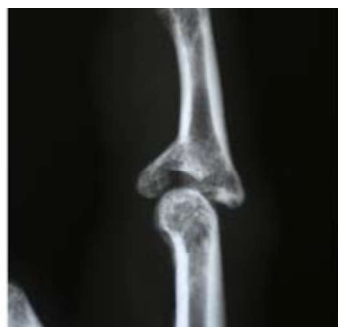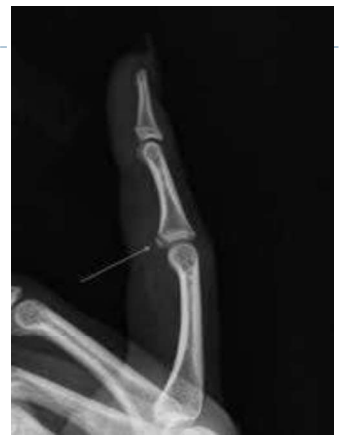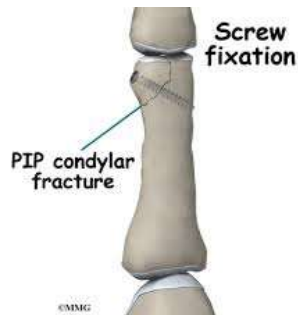


## P2

▶ Condyl # cave !

▶ Avulsie #  
ext insertie  
volaire plaat  
collaterale ligament

▶ Communiteive



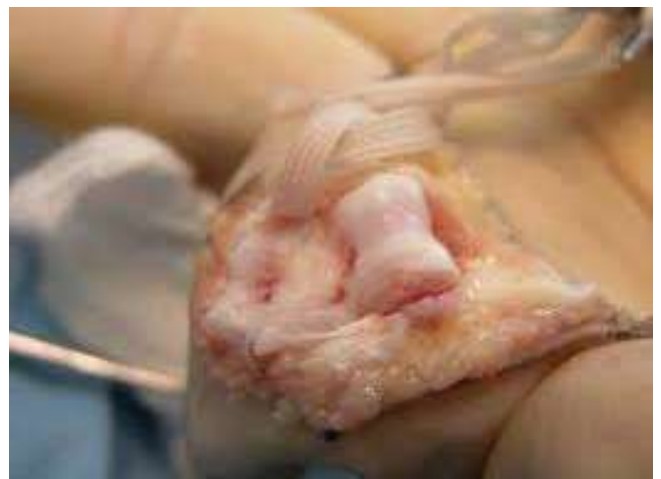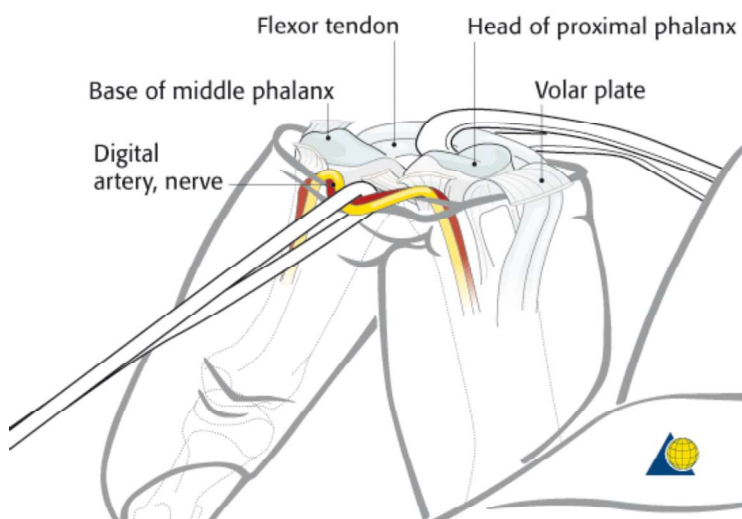
ORTHO.GENT

ORTHOPEDIE & TRAUMATOLOGIE



# “Shotgun approach”

---



---

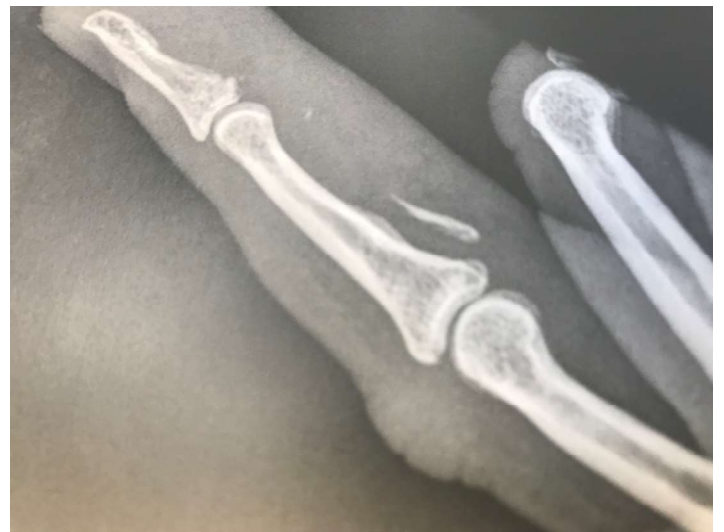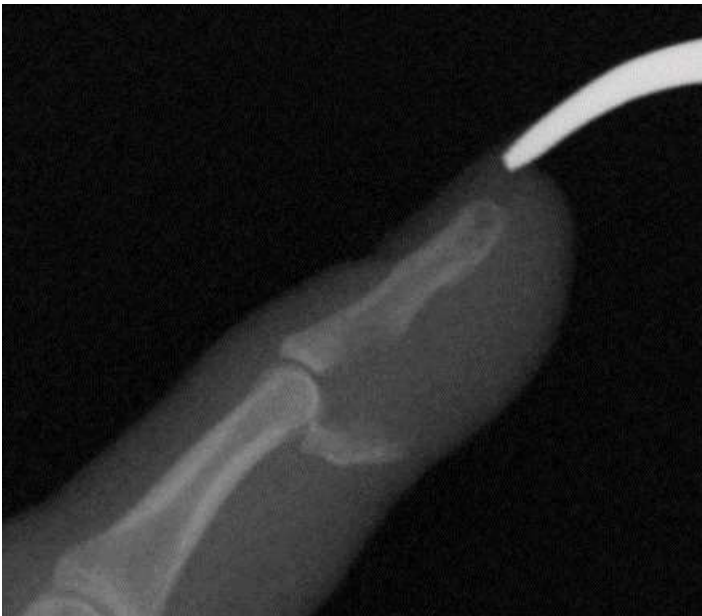ORTHO.GENT

ORTHOPEDIE & TRAUMATOLOGIE



# Rugby / jersey finger

---



---

ORTH.O.GENT

ORTHOPEDIE & TRAUMATOLOGIE

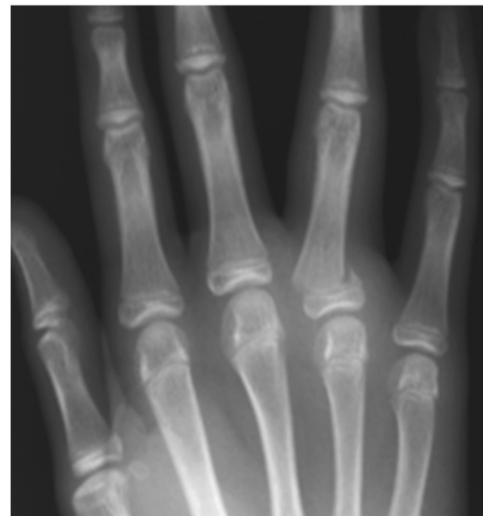
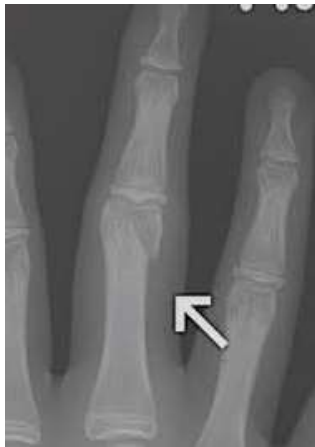
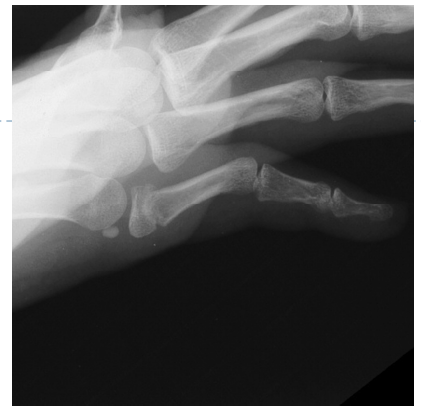

# P1

---

- ▶ Cfr P2
- ▶ Cavé basis #  
vooral bij ouderen



---

ORTHO.GENT

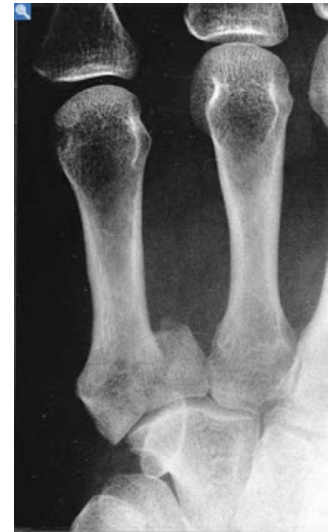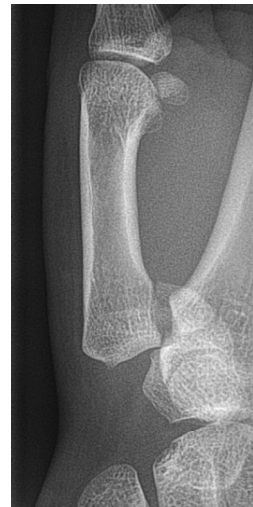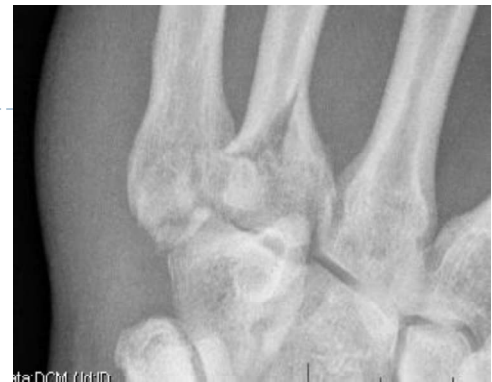ORTHOPEDIE & TRAUMATOLOGIE



## Metacarpaal #

---

- ▶ **Dislocatie basis**
- ▶ **Rotatie afwijking**  
5° => 1,5 cm overlap !
- ▶ **Angulatie**  
II III max 10°  
IV V tot 20 – 30°
- ▶ **Subcapitaal**  
tot 40° thv V
- ▶ **Bennett en reversed Bennett**



---

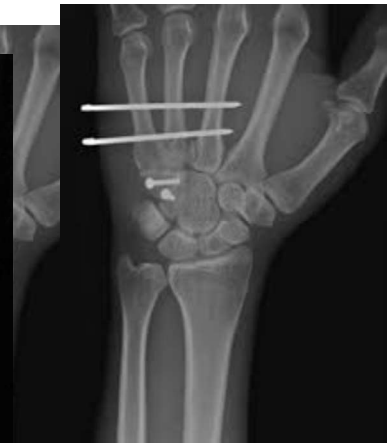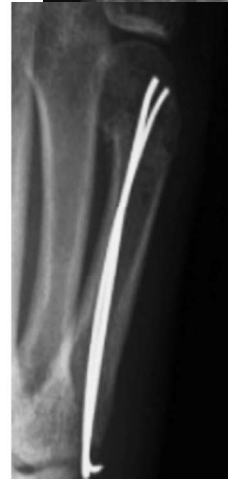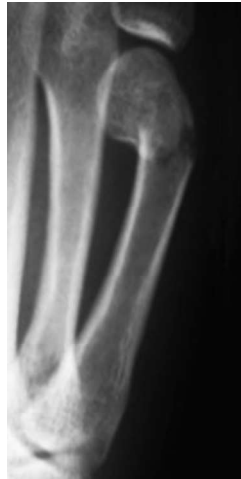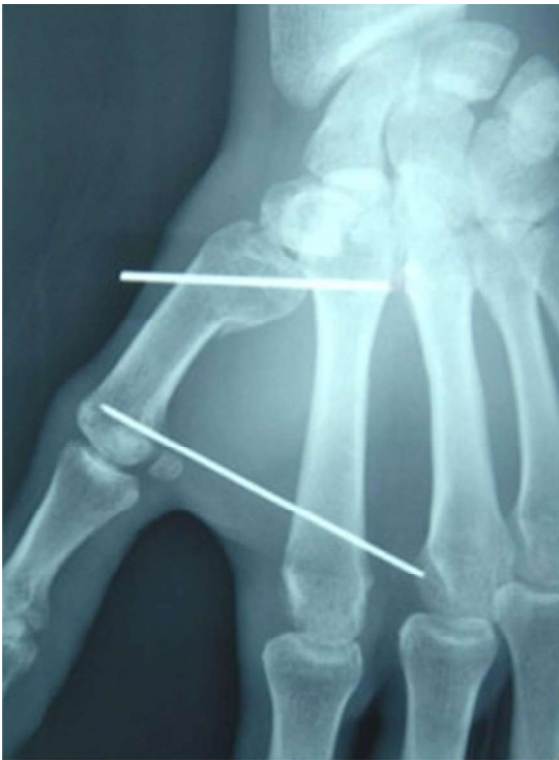ORTHO.GENT

ORTHOPEDIE & TRAUMATOLOGIE



# Isselin pinning / Foucher / interne fix.

---



ORTHO.GENT

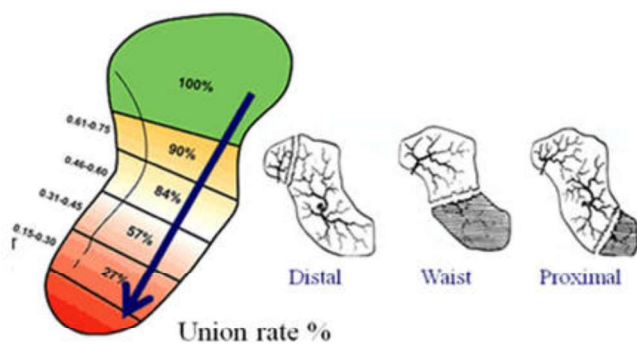
ORTHOPEDIE & TRAUMATOLOGIE



# handwortel

---

- ▶ Scaphoid
- ▶ Triquetrum
- ▶ Hamatum
- ▶ Anamnese
- ▶ Kliniek / testen
- ▶ Rx
- ▶ Ct

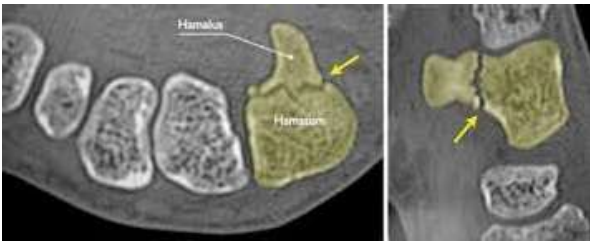
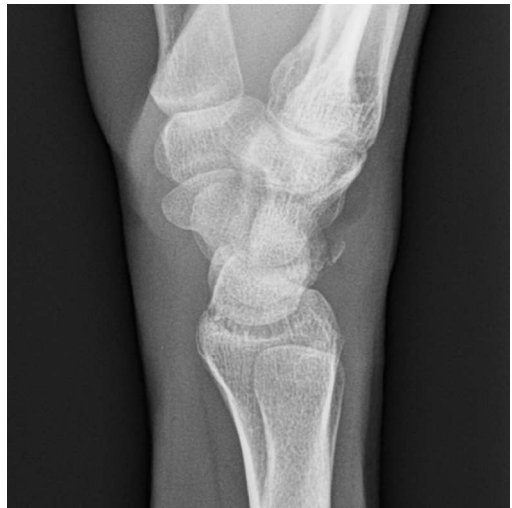
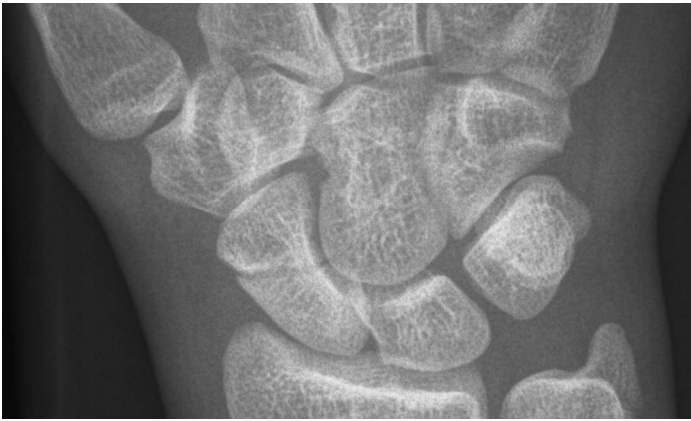
---

ORTHO.GENT

ORTHOPEDIE & TRAUMATOLOGIE





---

ORTHO.GENT

ORTHOPEDIE & TRAUMATOLOGIE



## Complicaties hand & carpus # zijn onvermijdelijk

---

▶ MAAR ;!!!!

het trauma dat aanleiding gaf tot de #

de behandeling zelf

de laattijdige behandeling

het gebrek aan behandeling

---

ORTHOPEDIE & TRAUMATOLOGIE

ORTHOPEDIE & TRAUMATOLOGIE



## Take home message

---

- ▶ # hand als **ernstig** nemen
- ▶ **Overleg** met radioloog/ goede info
- ▶ Bij twijfel **snell** doorverwijzen
- ▶ **Open** letsel P 3 kinderen = ernstig !
- ▶ **Correcte** ( comfortable ) immobilisatie