

Gepersonaliseerde knieprothese

Dr. Dobbelaere Andreas



ORTHO.TOMORROW 25.11.23



Gepersonaliseerde Knieprothese

Dr. Dobbelaere Andreas



Anatomische variatie

- Alignement
- Morfologie
- Wekedelenenveloppe

Artrose patroon

- Unicompartmentel artrose
- Tricompartmentele artrose

Knieprothese

- Unicompartmentele prothese
- Totale knieprothese
- Robotchirurgie
- Op maat gemaakte prothese (custom made TKA)

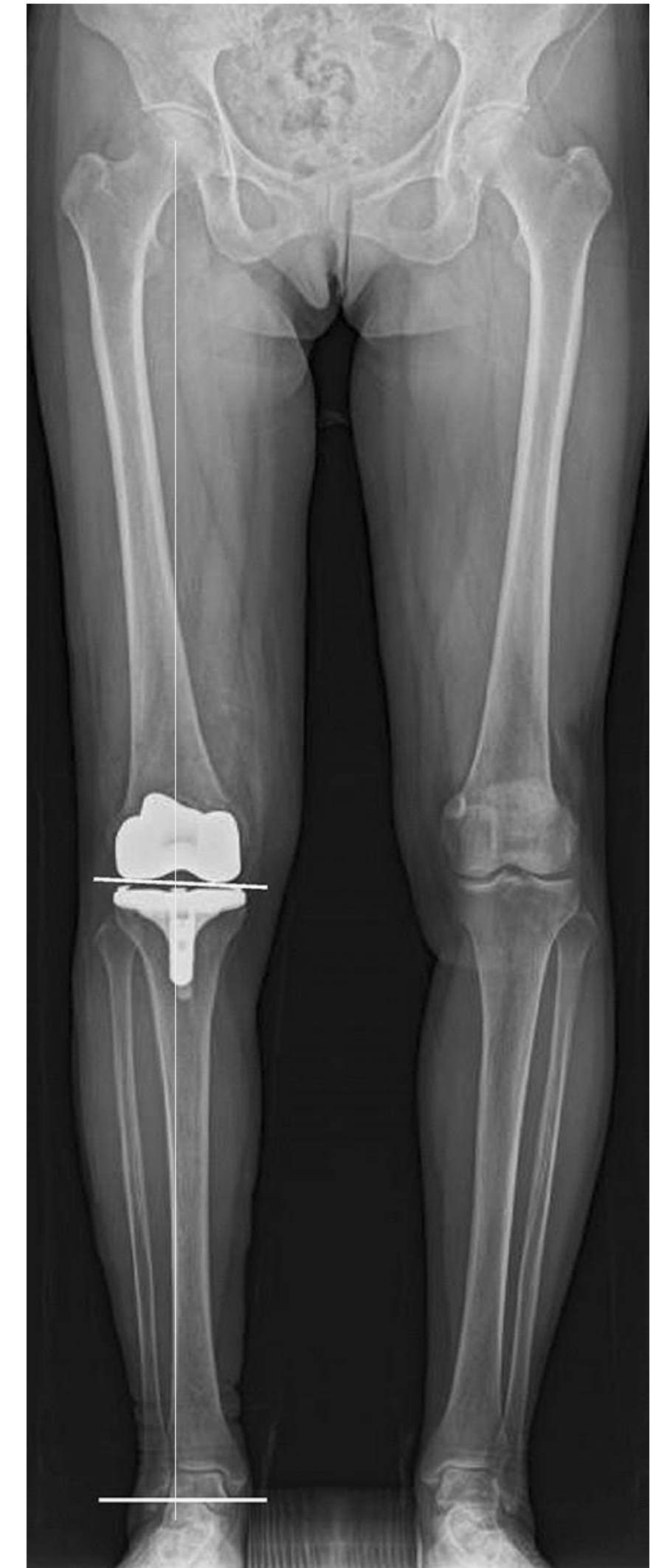Vroeger: anno 2015

Artrose knie



TKP

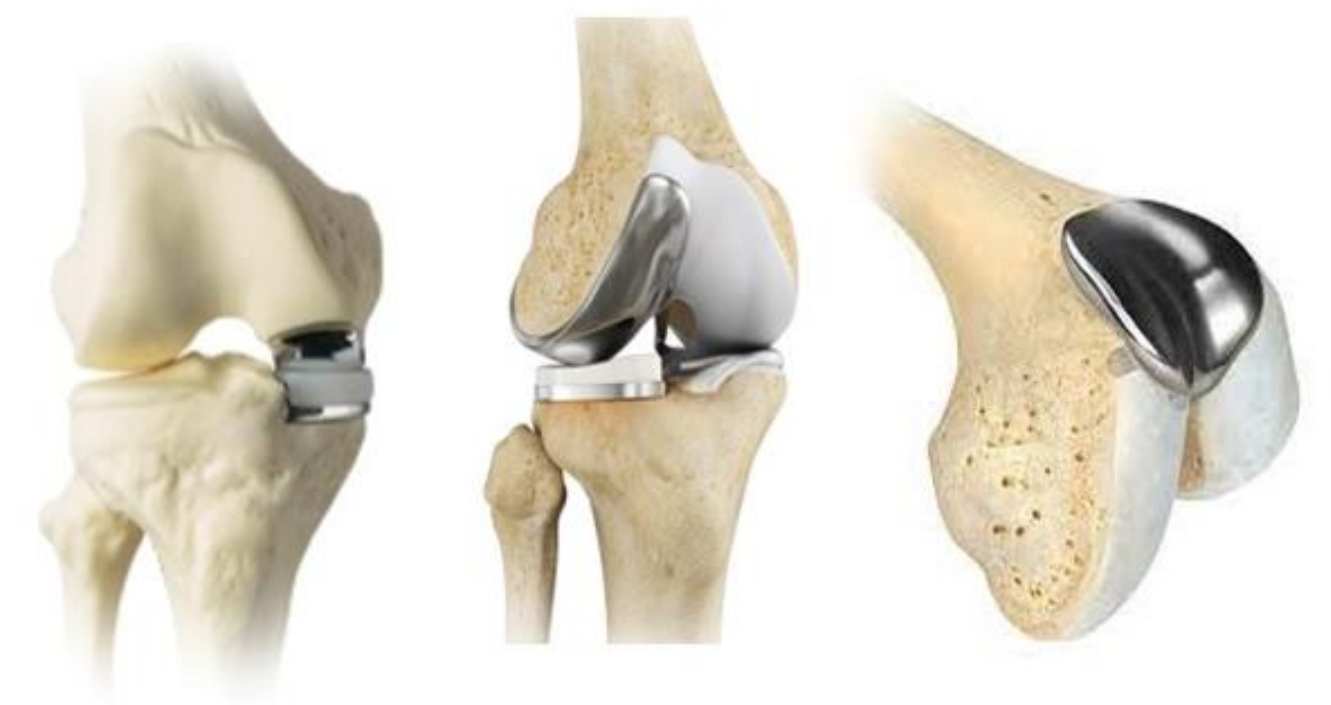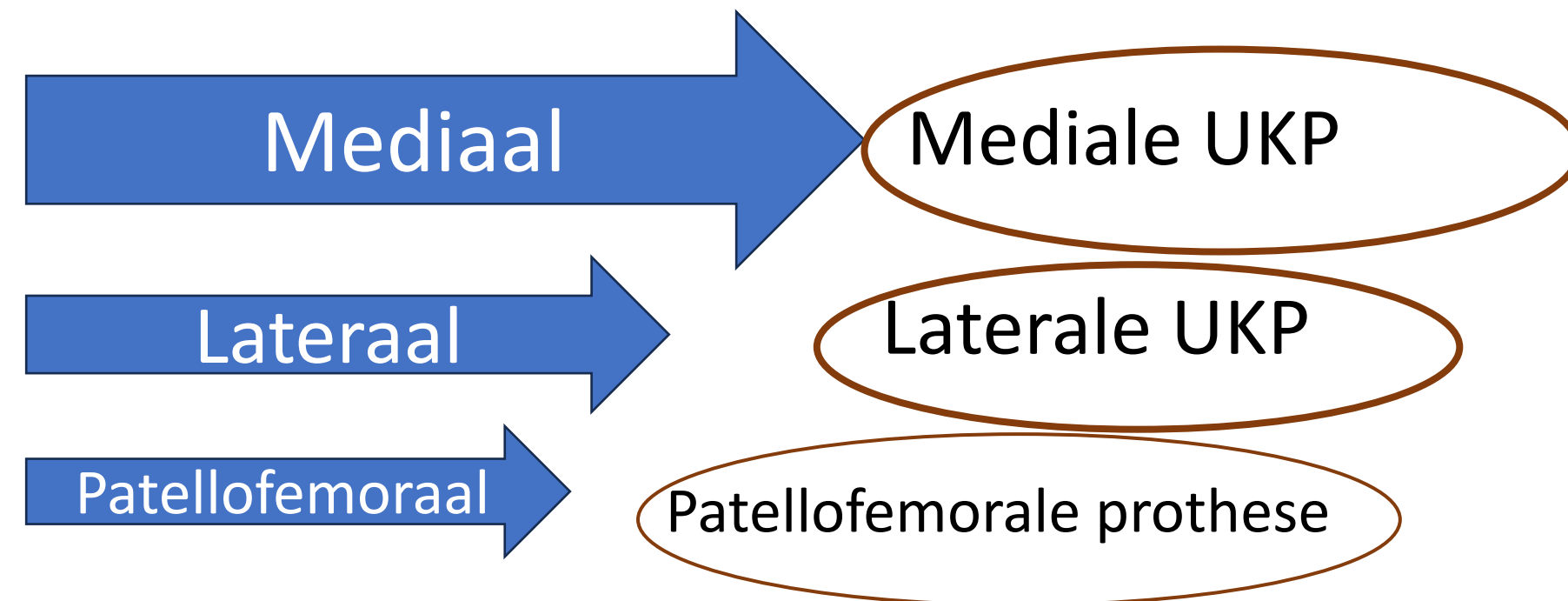
“Patiententevredenheid na TKP: 80-85%”



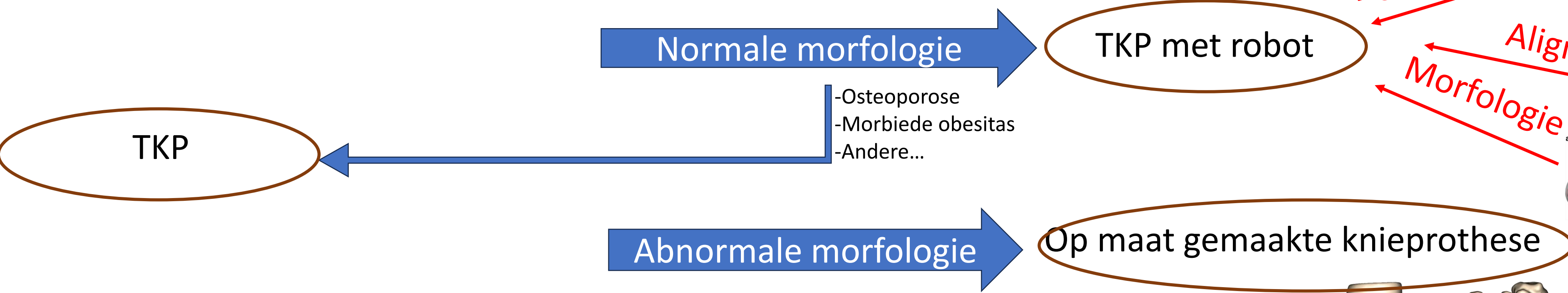
Protocol gepersonaliseerde knieprothese

Locatie artrose

1 compartiment



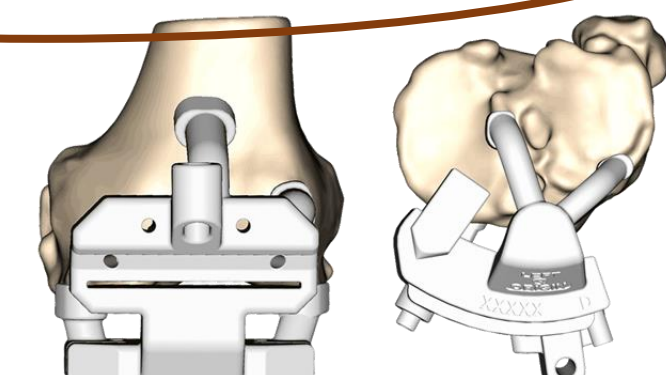
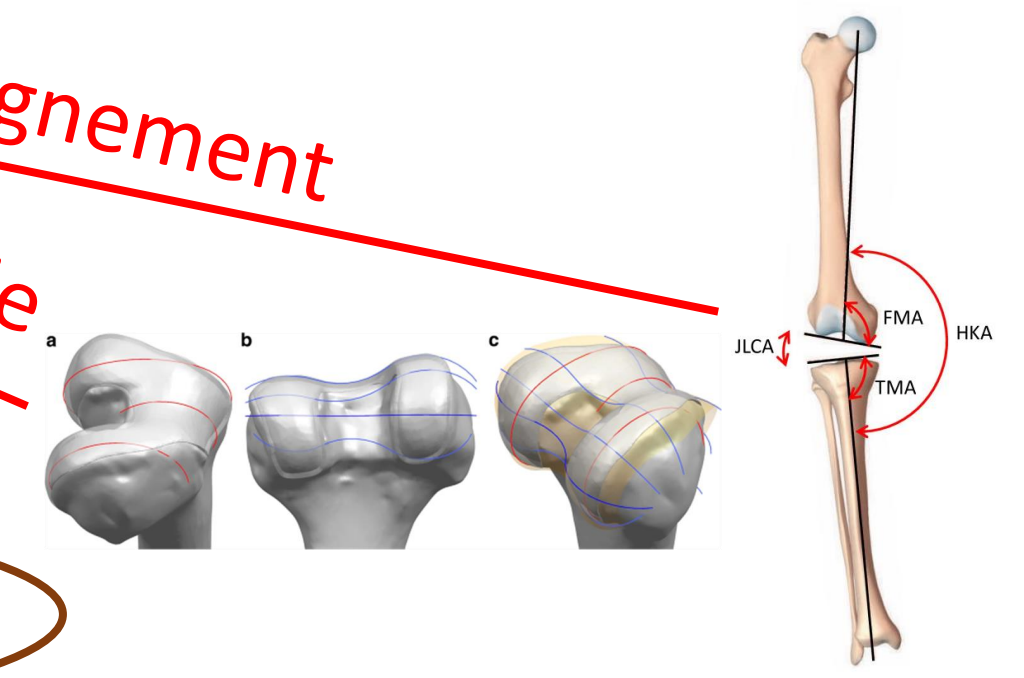
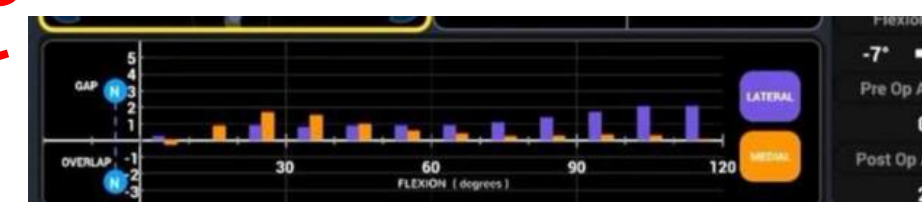
2 of 3 compartimenten



Ligamentaire balans

Alignement

Morfologie



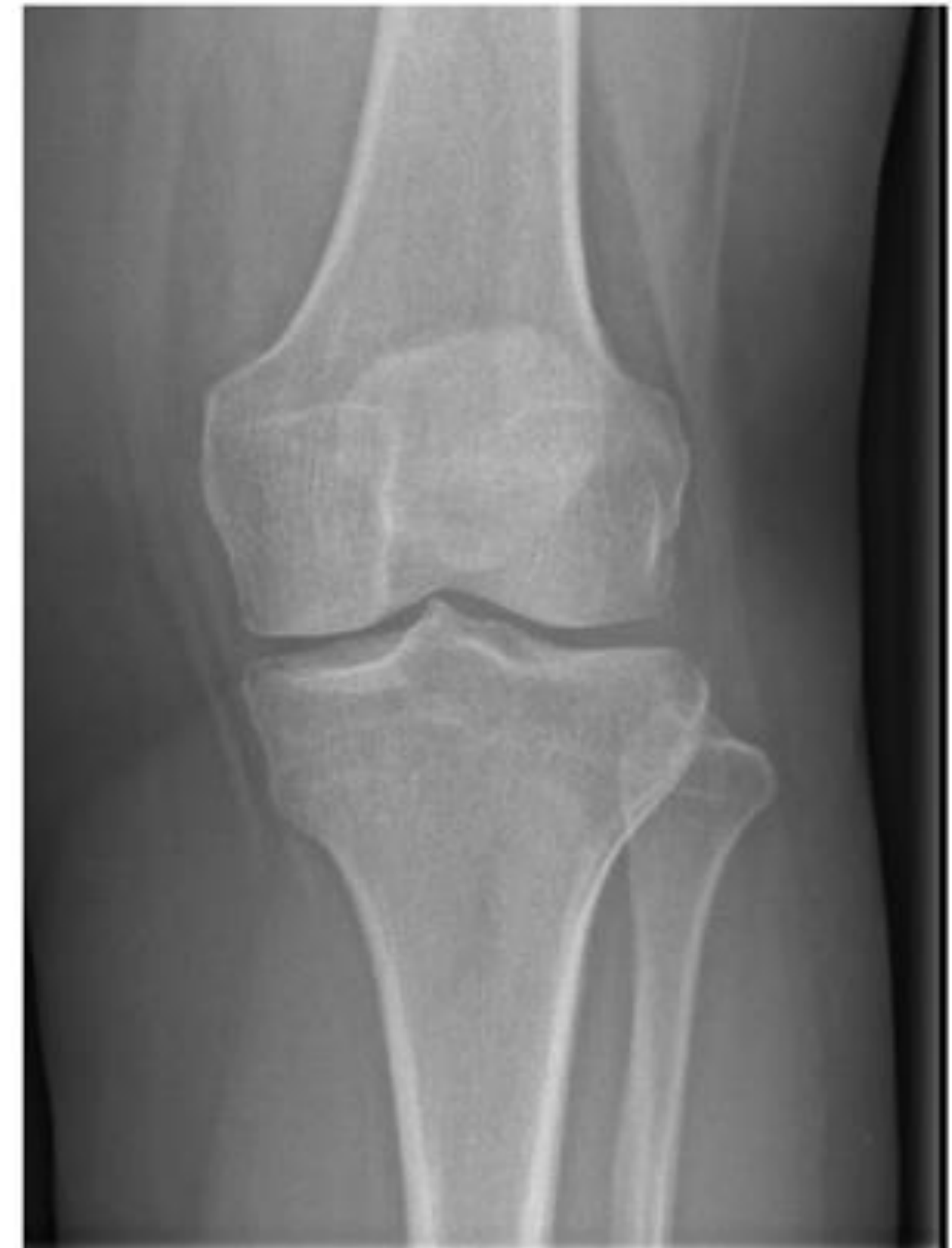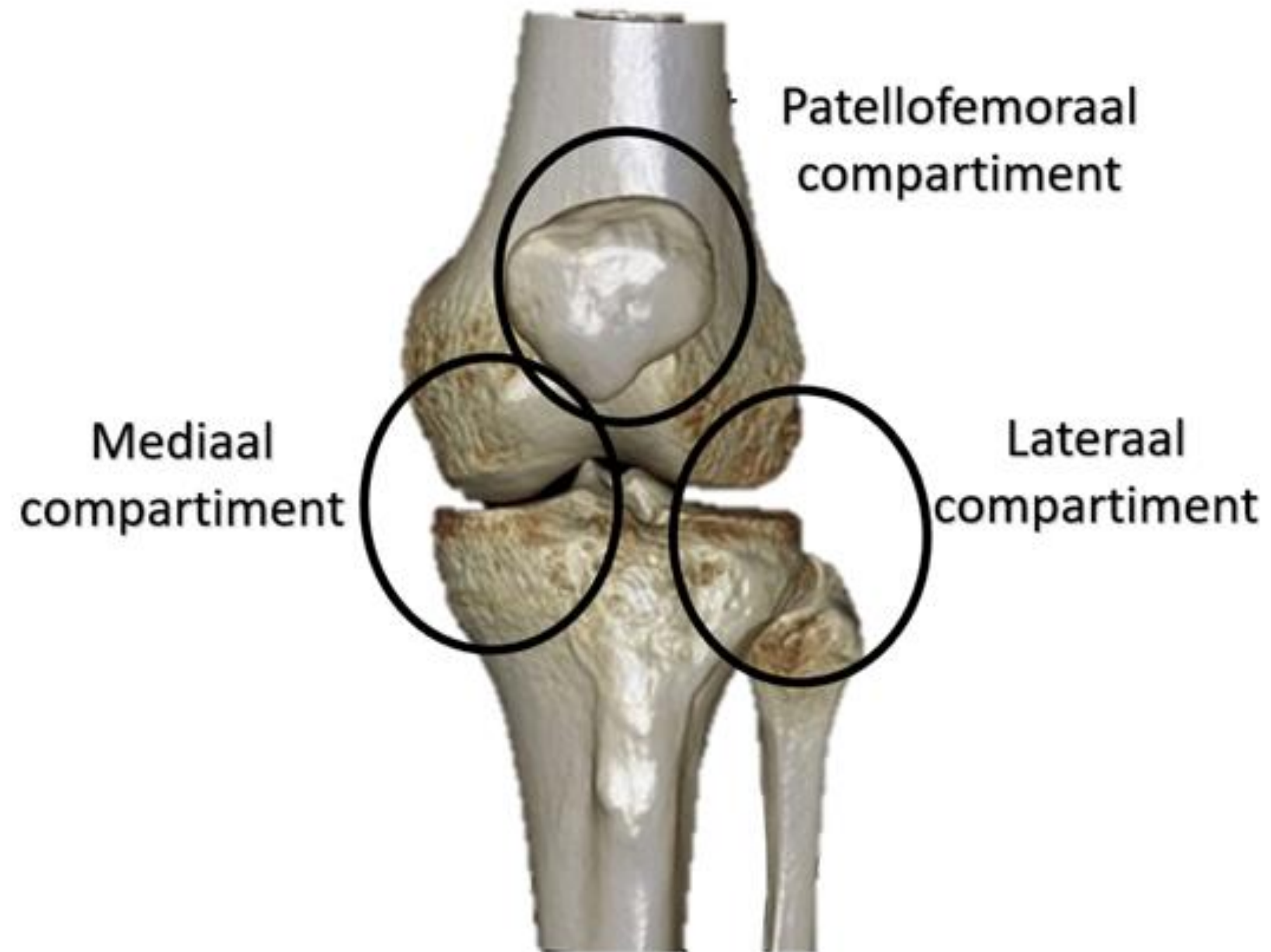
Atrose patroon

- Unicompartimentel artrose
- Tricompartimentele artrose








ORTHO.GENT

ORTHOPEDIE & TRAUMATOLOGIE

Compartimenten van de knie



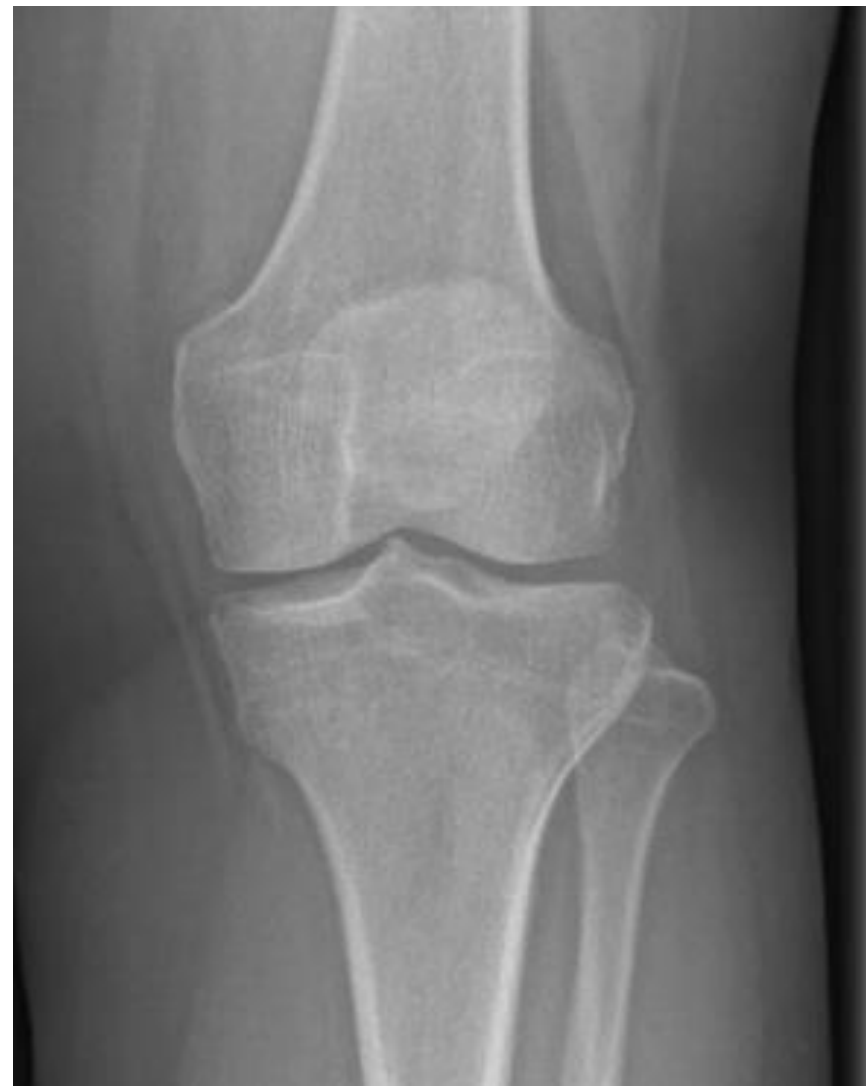Artrose: Unicompartmenteel VS Tricompartmenteel

Single Compartmental			Bicompartmental			Tricompartmental
Isolated Medial Tibiofemoral	Isolated Lateral Tibiofemoral	Isolated Patellofemoral	Combined Medial Tibiofemoral and Patellofemoral	Combined Lateral Tibiofemoral and Patellofemoral	Combined Medial and Lateral Tibiofemoral	Combined Medial and Lateral Tibiofemoral and Patellofemoral
						

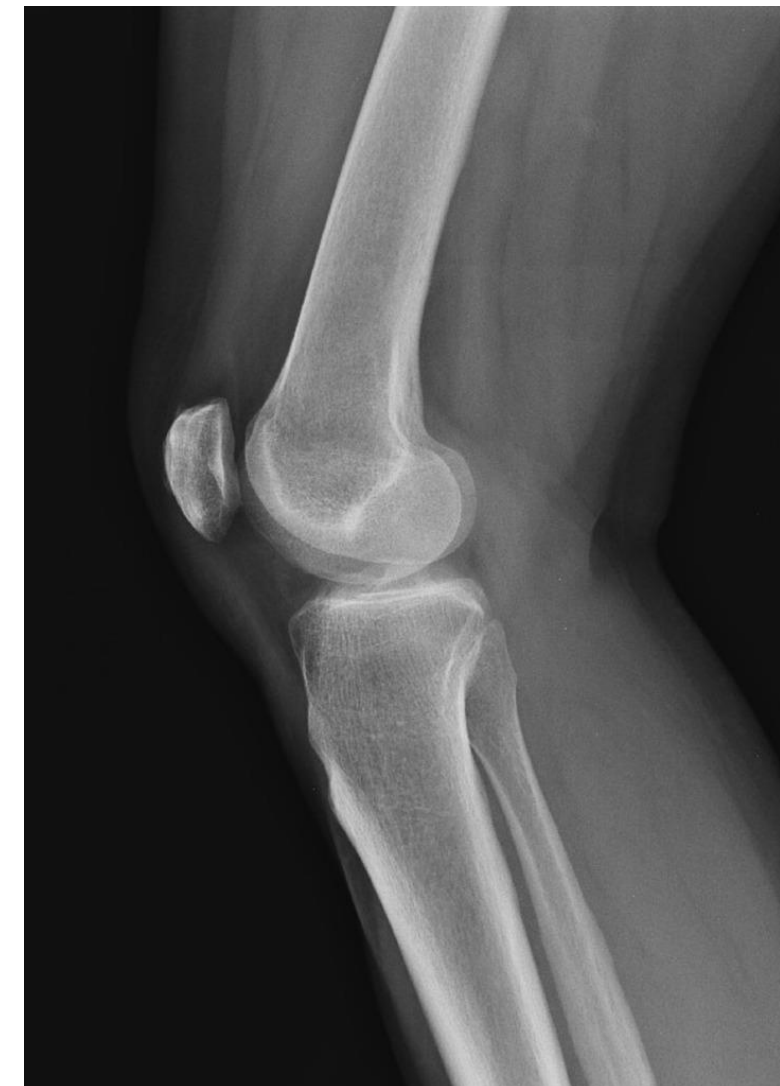40%

Hoe artrosepatroon herkennen?

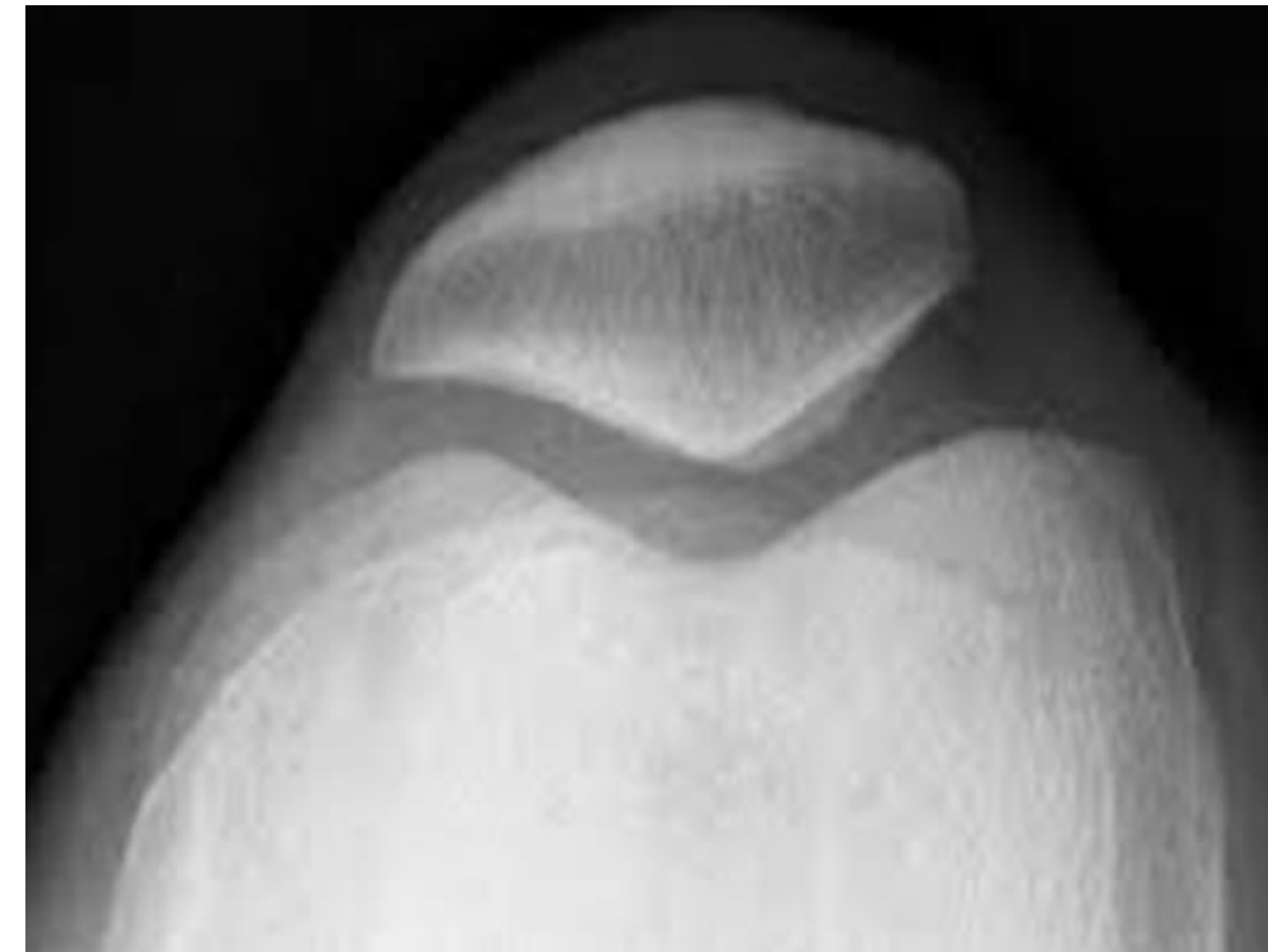- Radiografie: 4x opnames



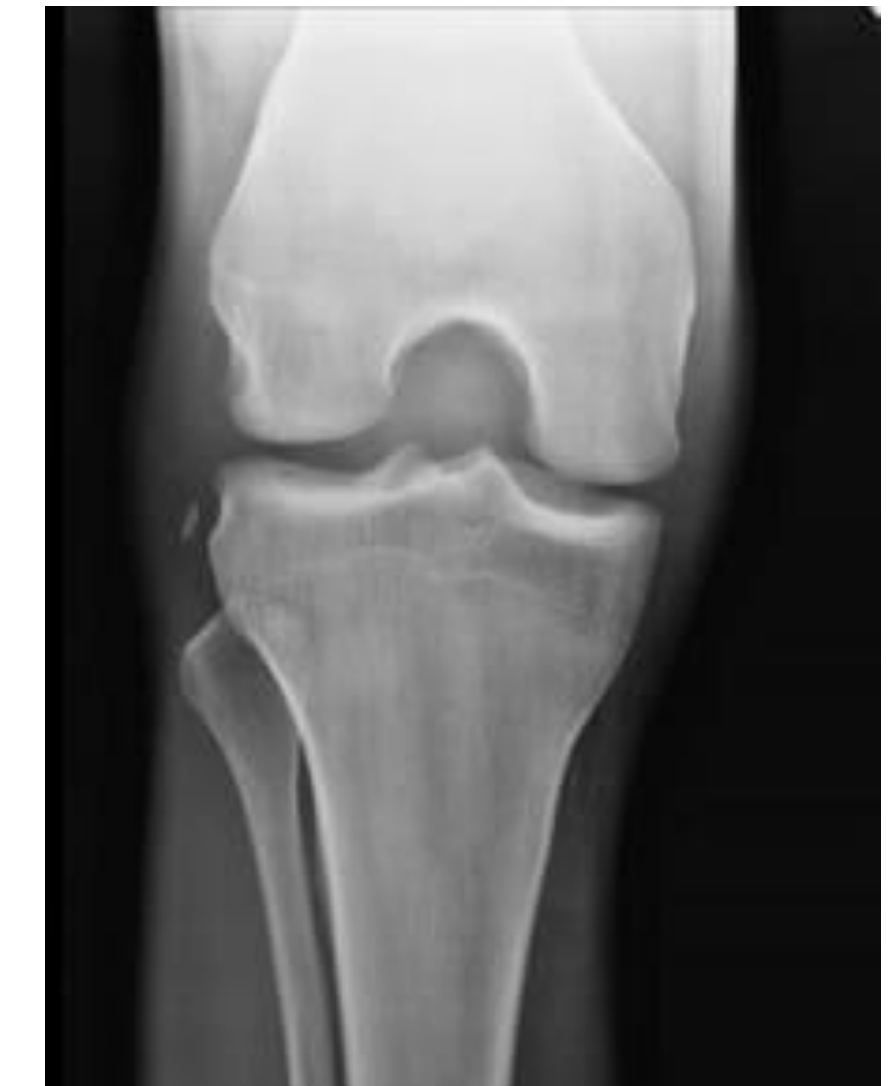FACE



PROFIEL



PATTELAIR

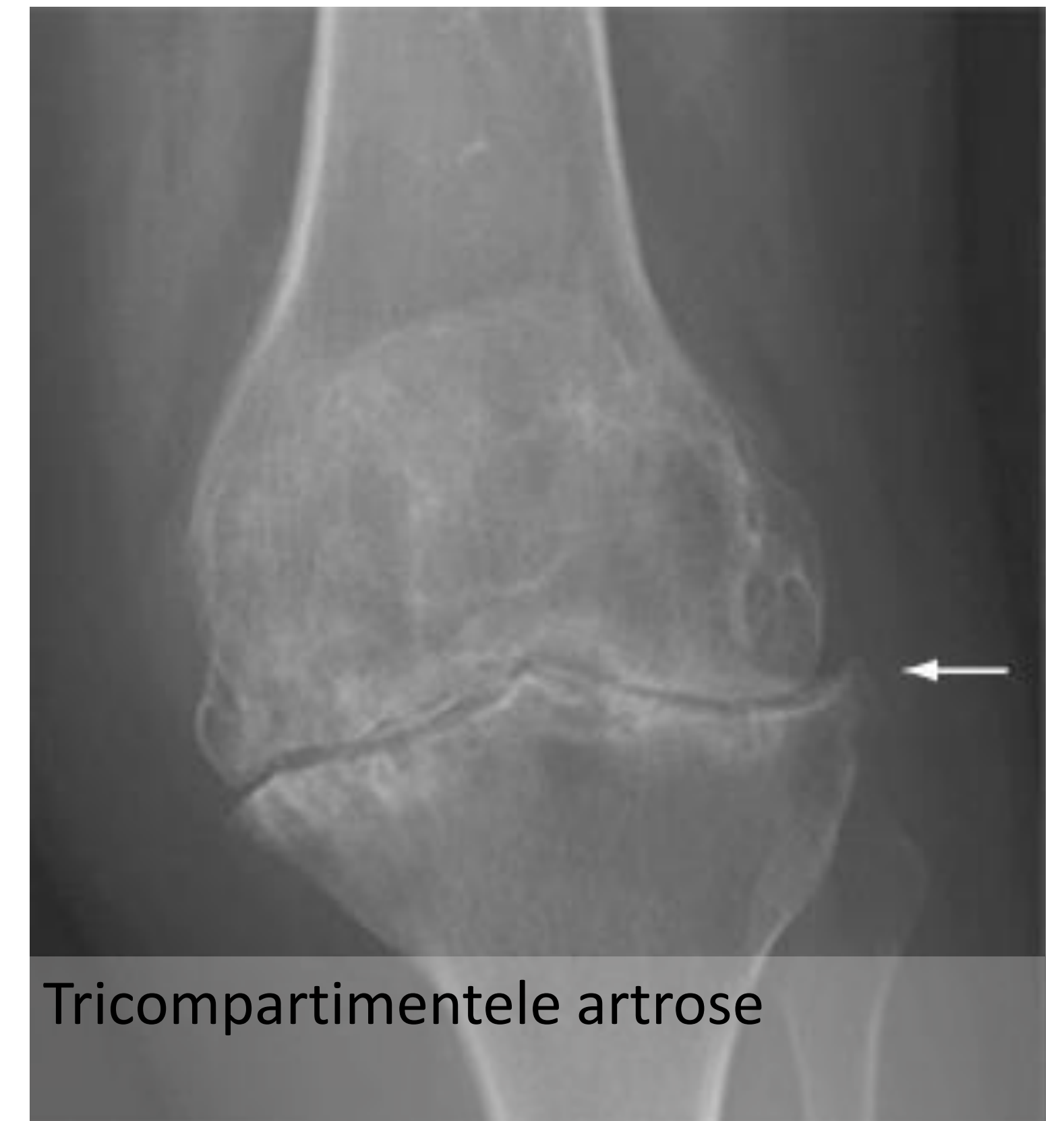
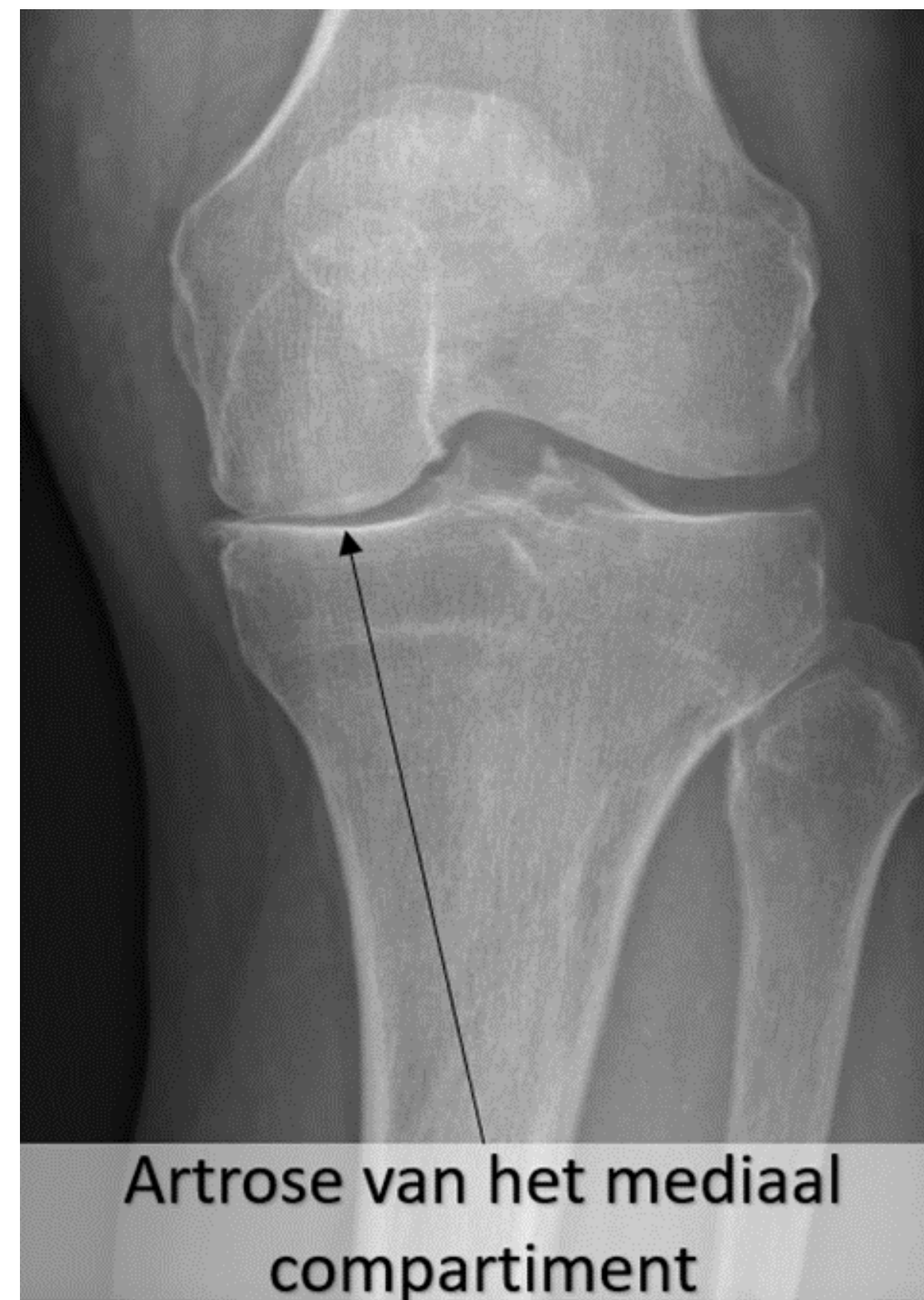
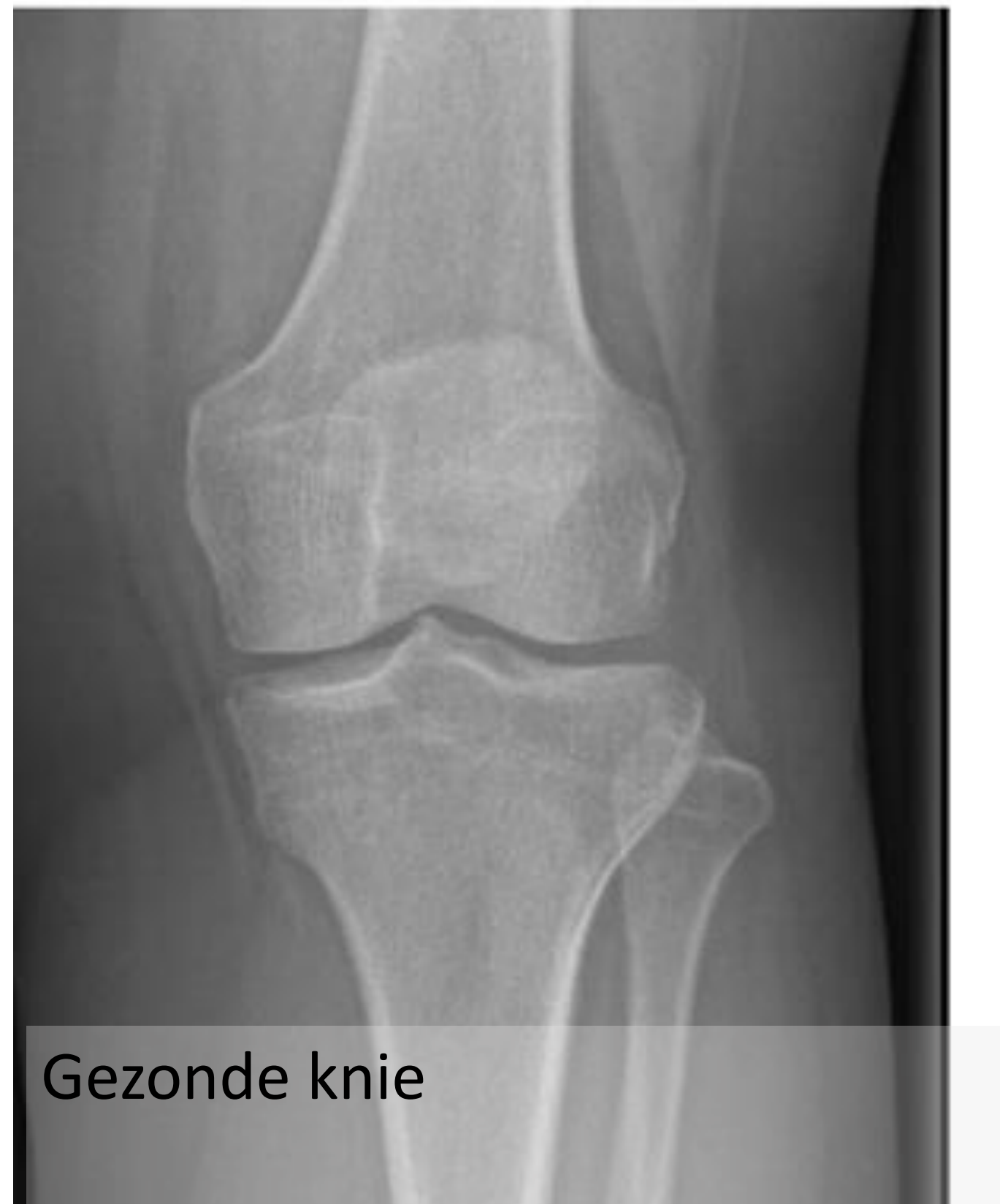SCHÜSS

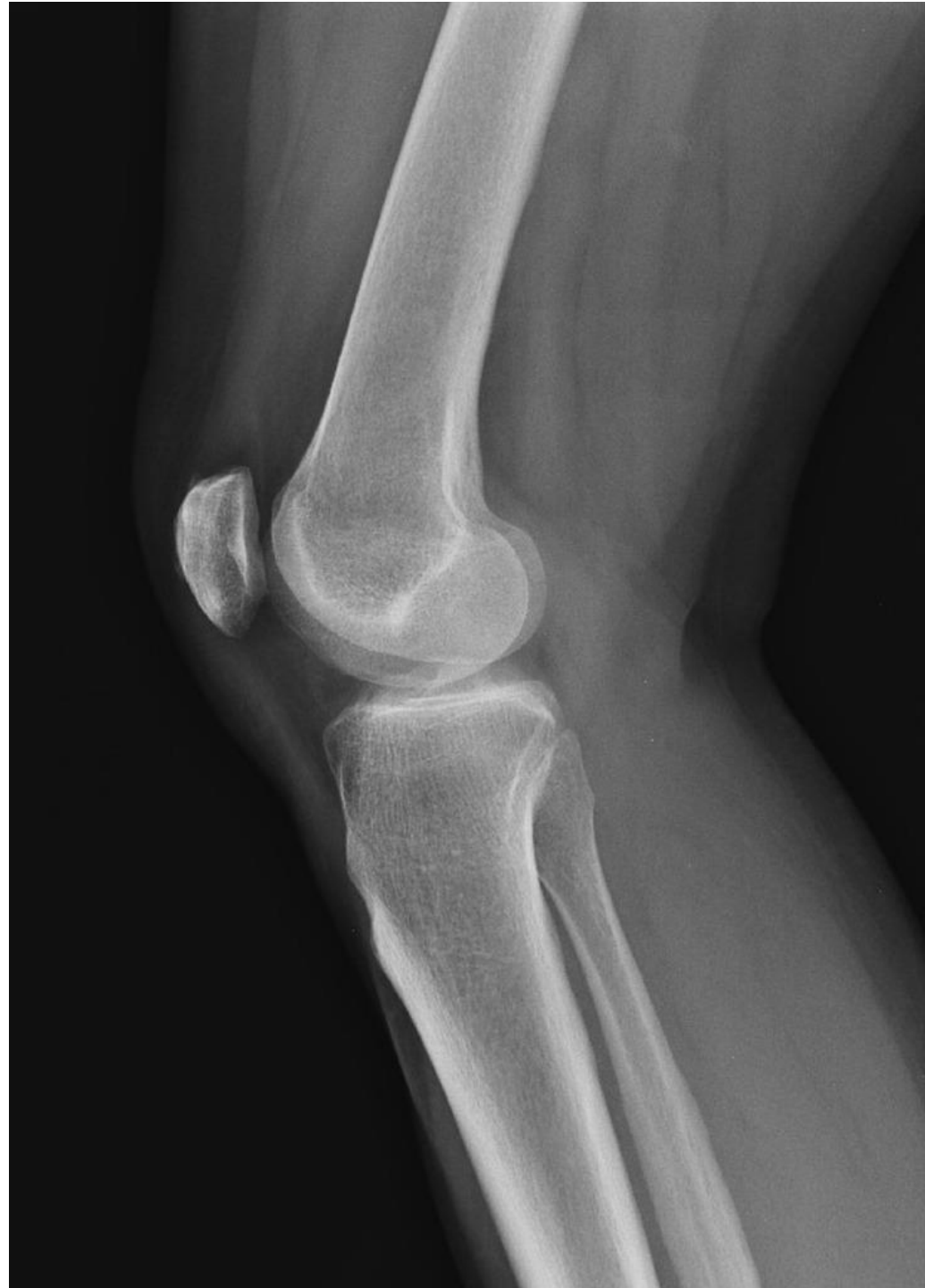1) Staande opname

=Voorachterwaartse opname

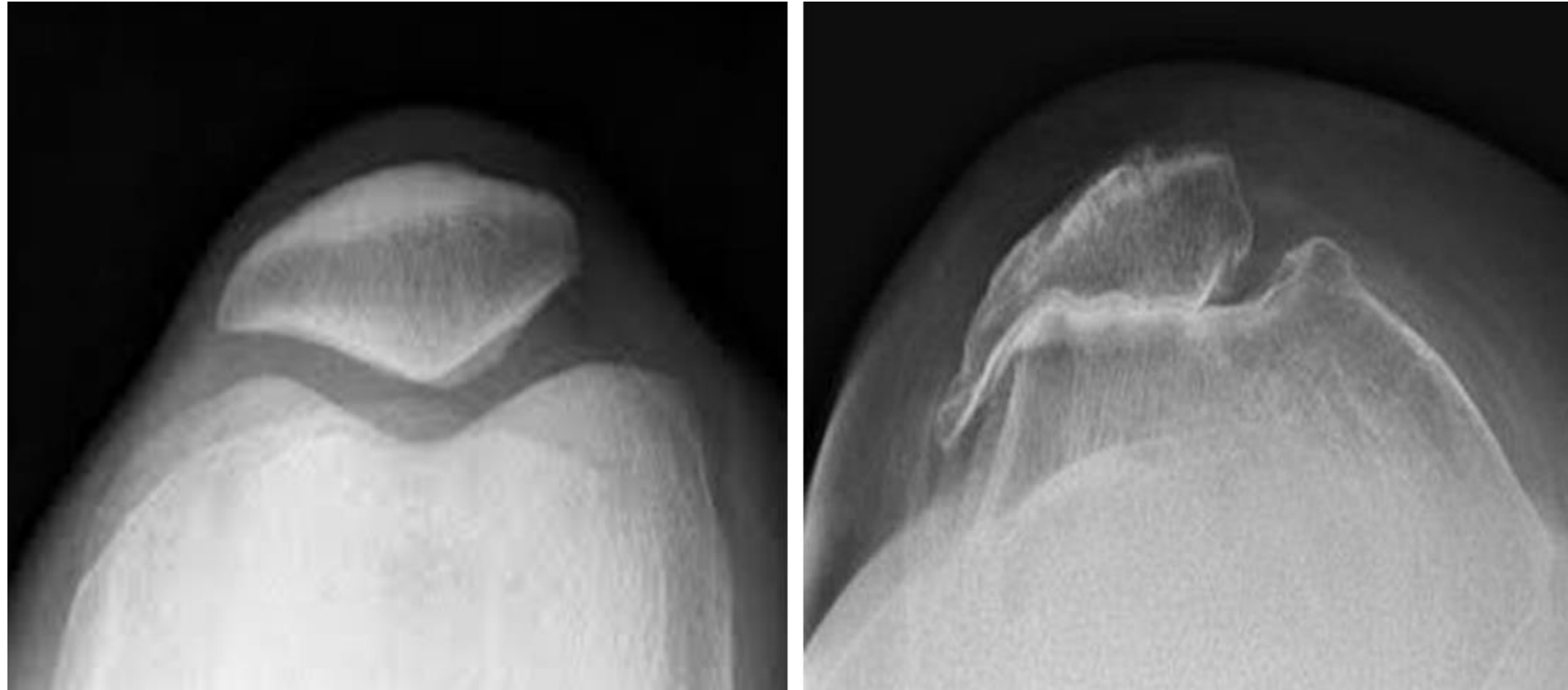=Face opname



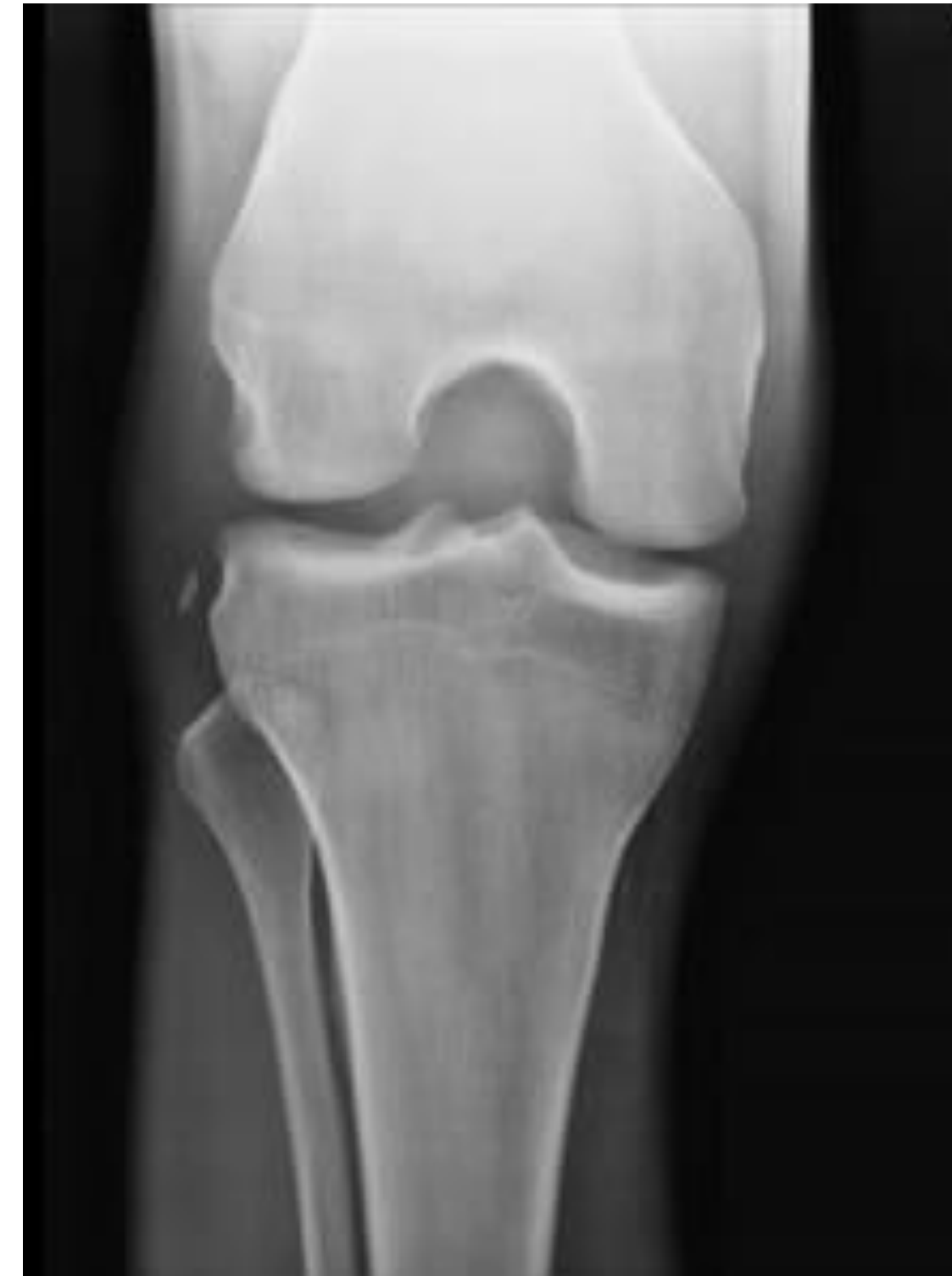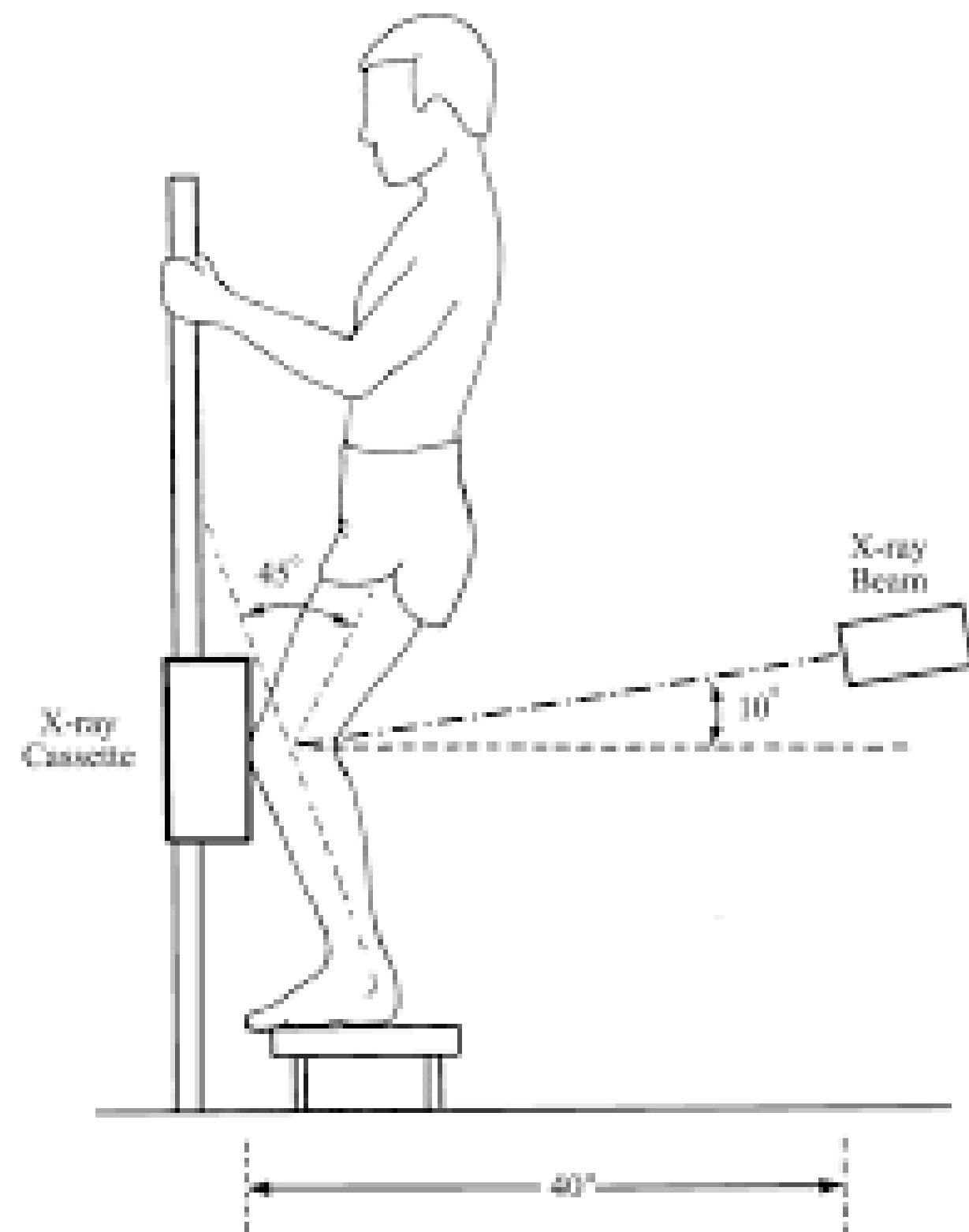
2) Profiel opname



3) Patellaire opname

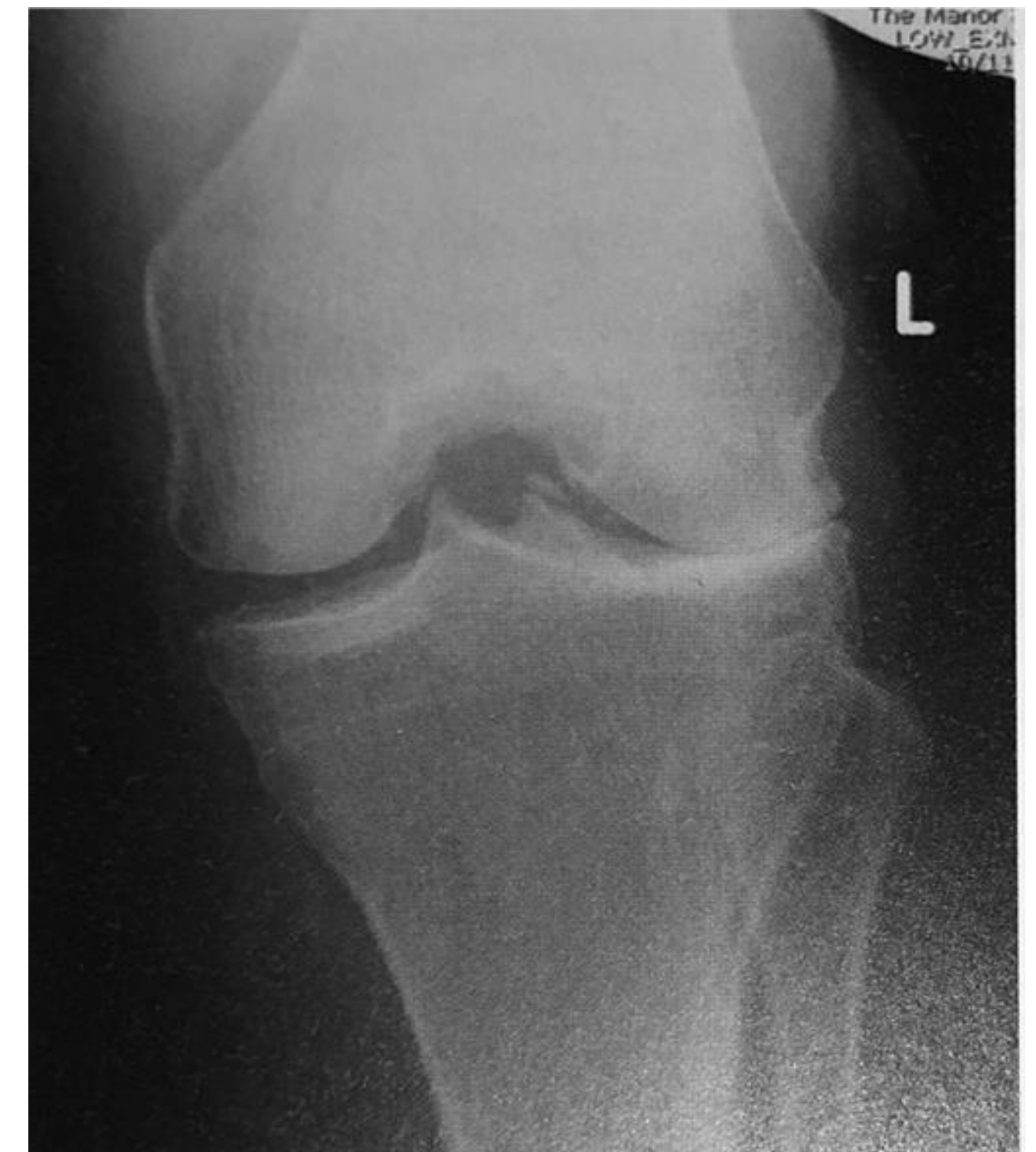

4) Schüss opname= Rosenberg View



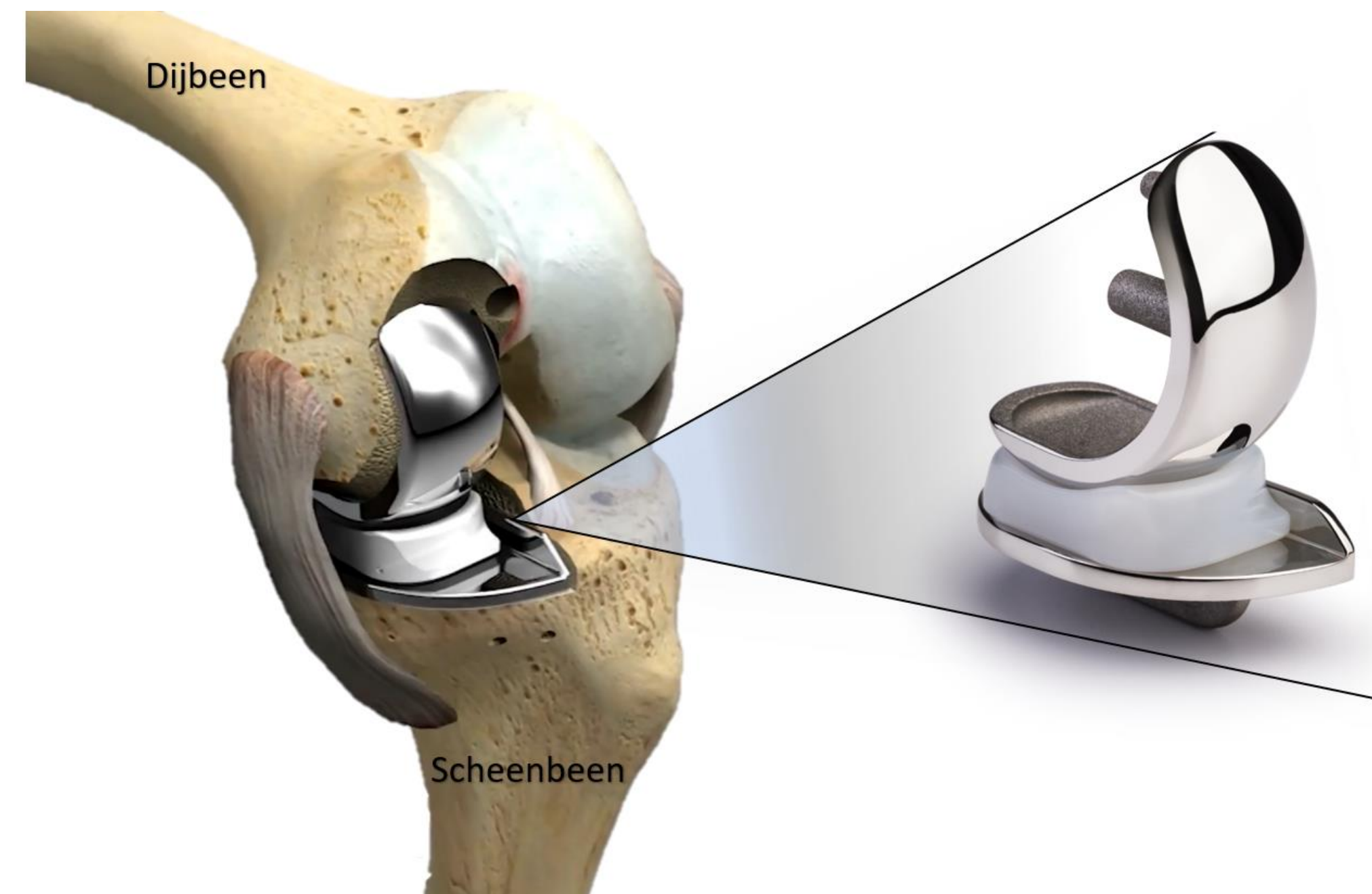
Geïsoleerde Laterale artrose

- Vaak gemist
- laterale artrose = flexie ziekte
- Locatie artrose: posterieure condyl
- Typisch bij valgus knie + laterale meniscectomie



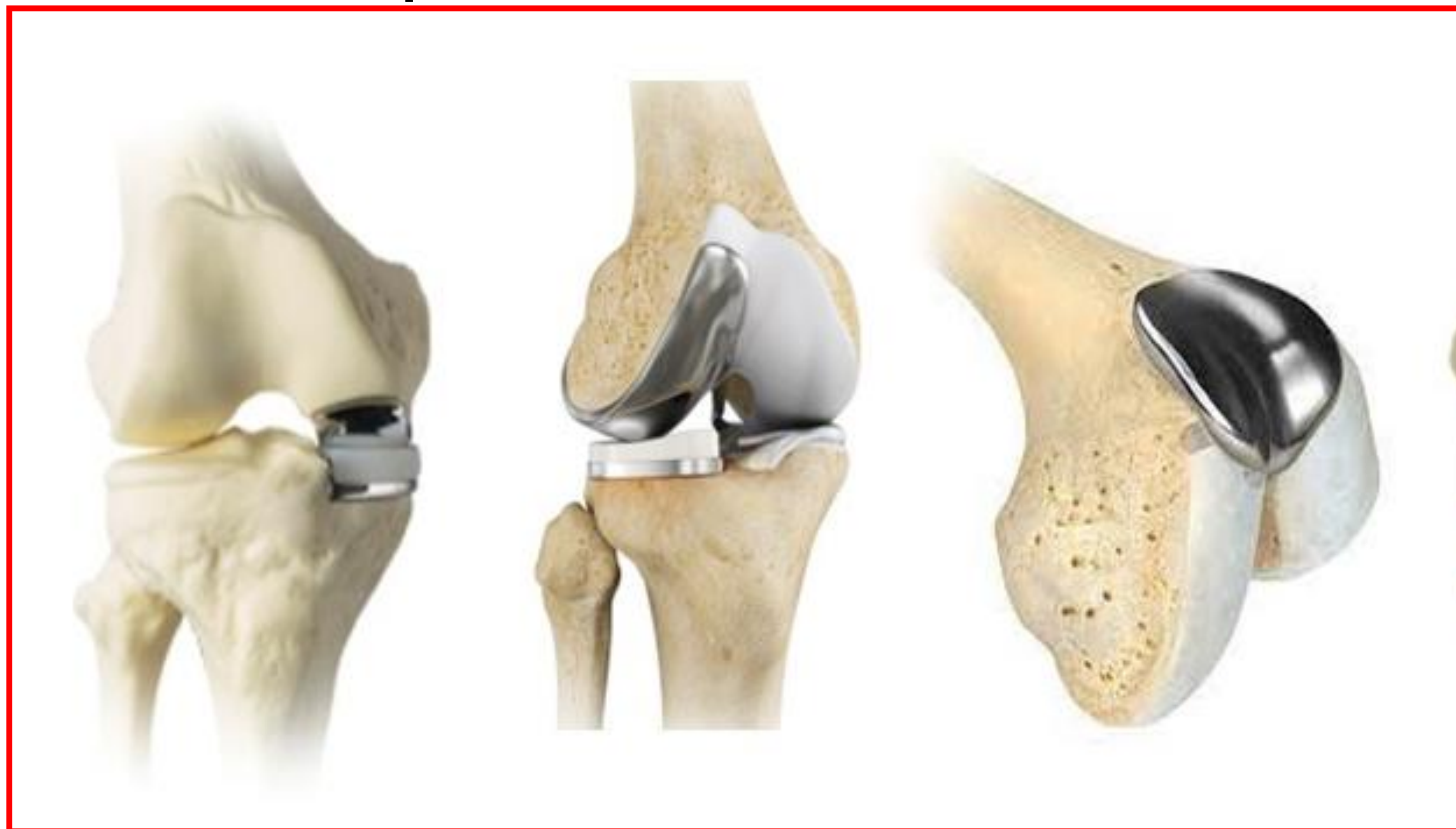Conclusie: artrosepatroon








- Diagnose: 4x RX opnames
- Schüss opname: nuttig om geïsoleerde laterale artrose op te sporen
- Geïsoleerde unicompartimentele artrose = **halve knieprothese**



Unicompartimentele knieprothese (UKP)

= halve knieprothese



Single Compartmental			Bicompartamental			Tricompartamental
Isolated Medial Tibiofemoral	Isolated Lateral Tibiofemoral	Isolated Patellofemoral	Combined Medial Tibiofemoral and Patellofemoral	Combined Lateral Tibiofemoral and Patellofemoral	Combined Medial and Lateral Tibiofemoral	Combined Medial and Lateral Tibiofemoral and Patellofemoral
						

40%

5%

1-2%

50%

Totale knieprothese met ROBOT

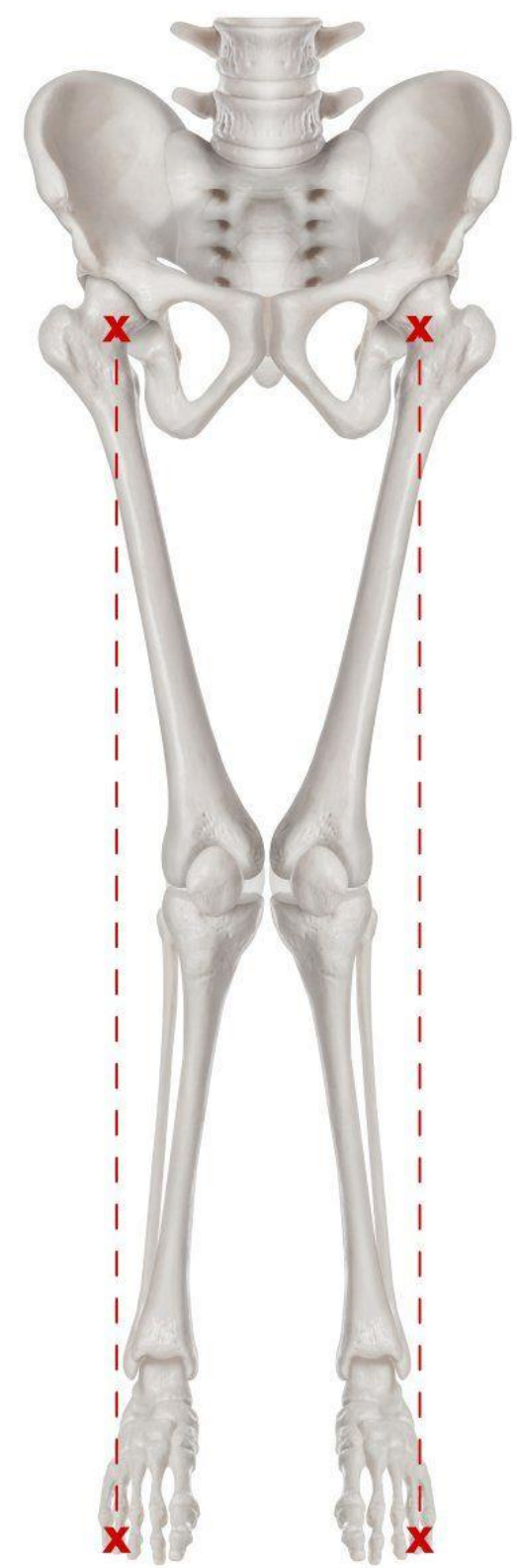
Anatomische variatie

- Aligement
- Morfologie
- Wekedelenenveloppe

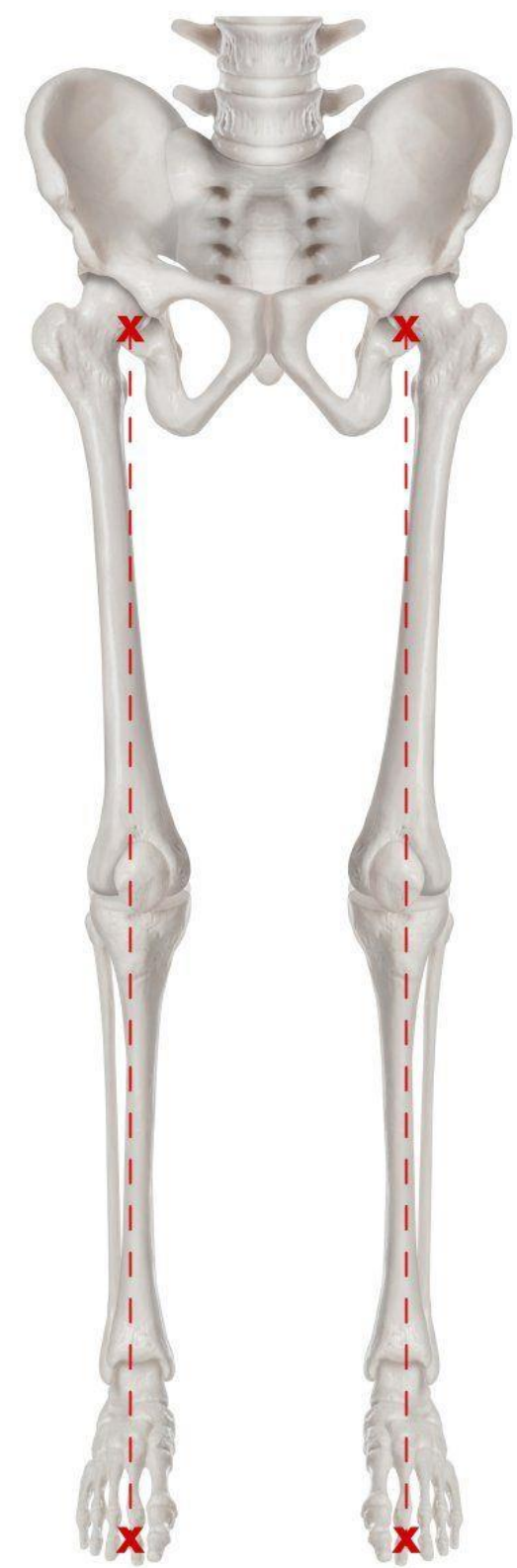

Anatomische variatie

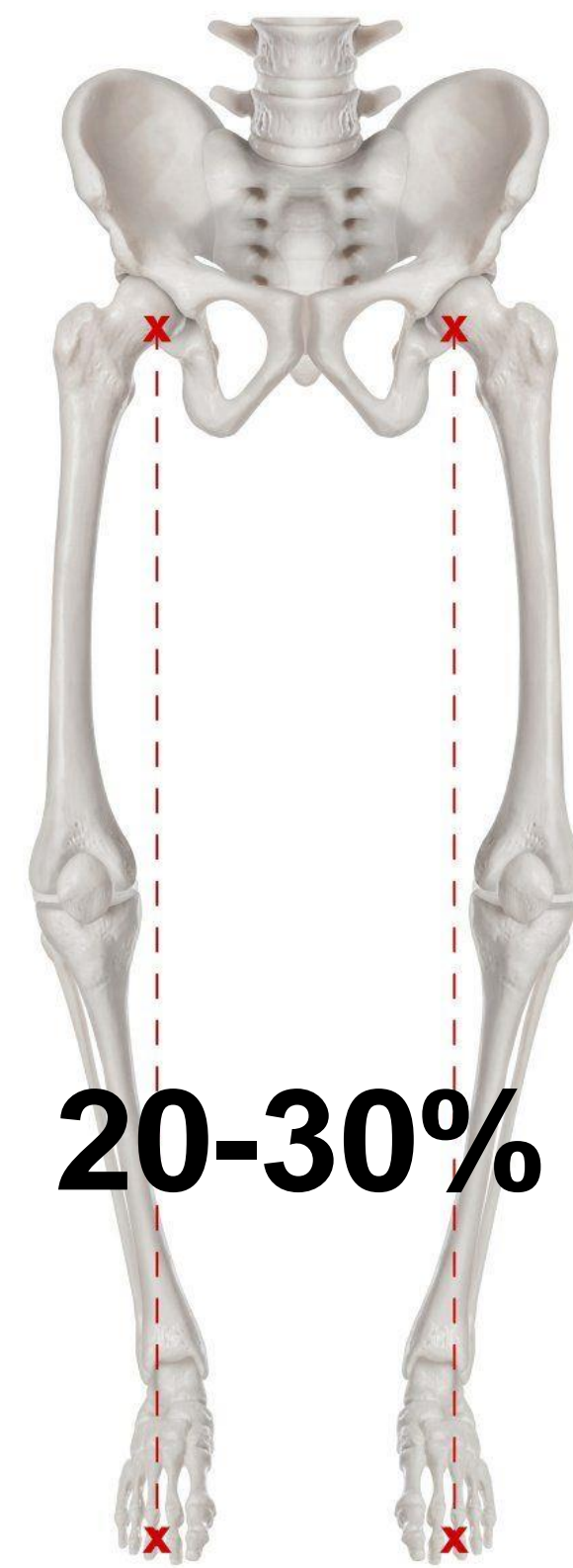
- Aligment
- Morfologie
- Wekedelenenveloppe



KNOCK - KNEE

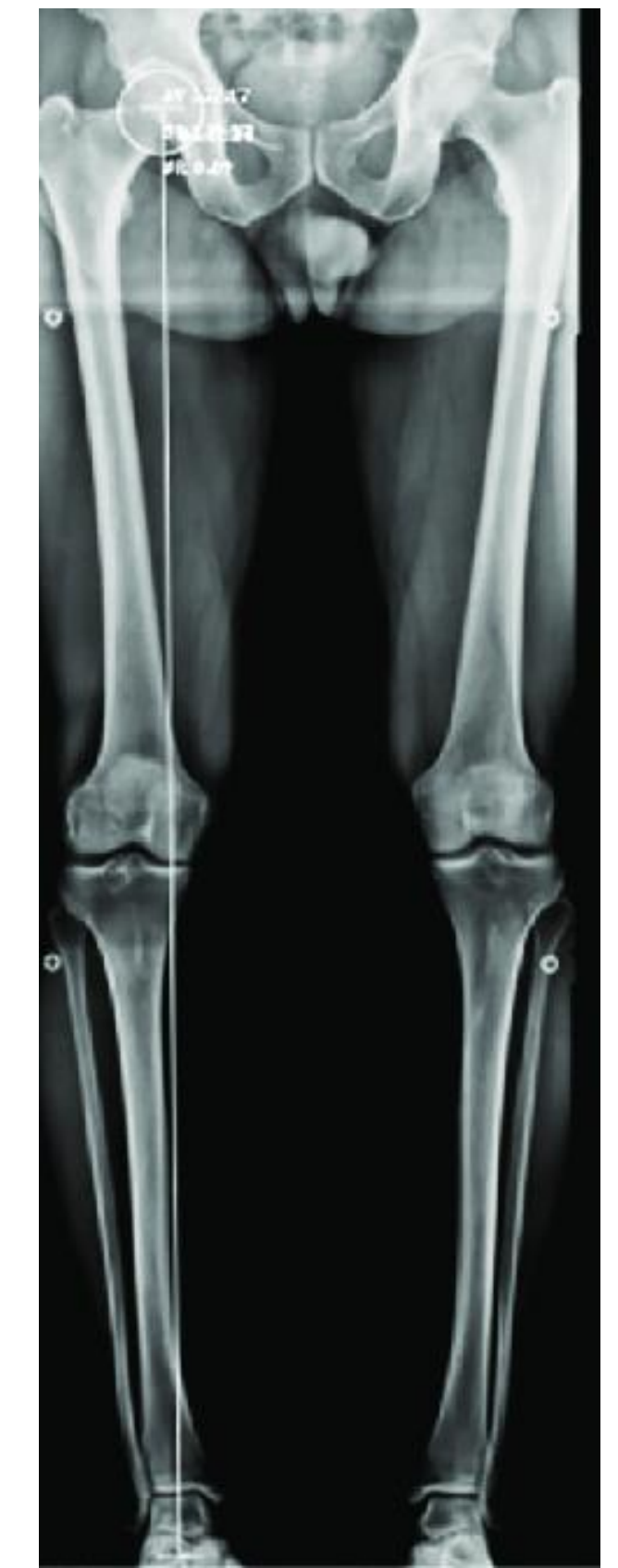

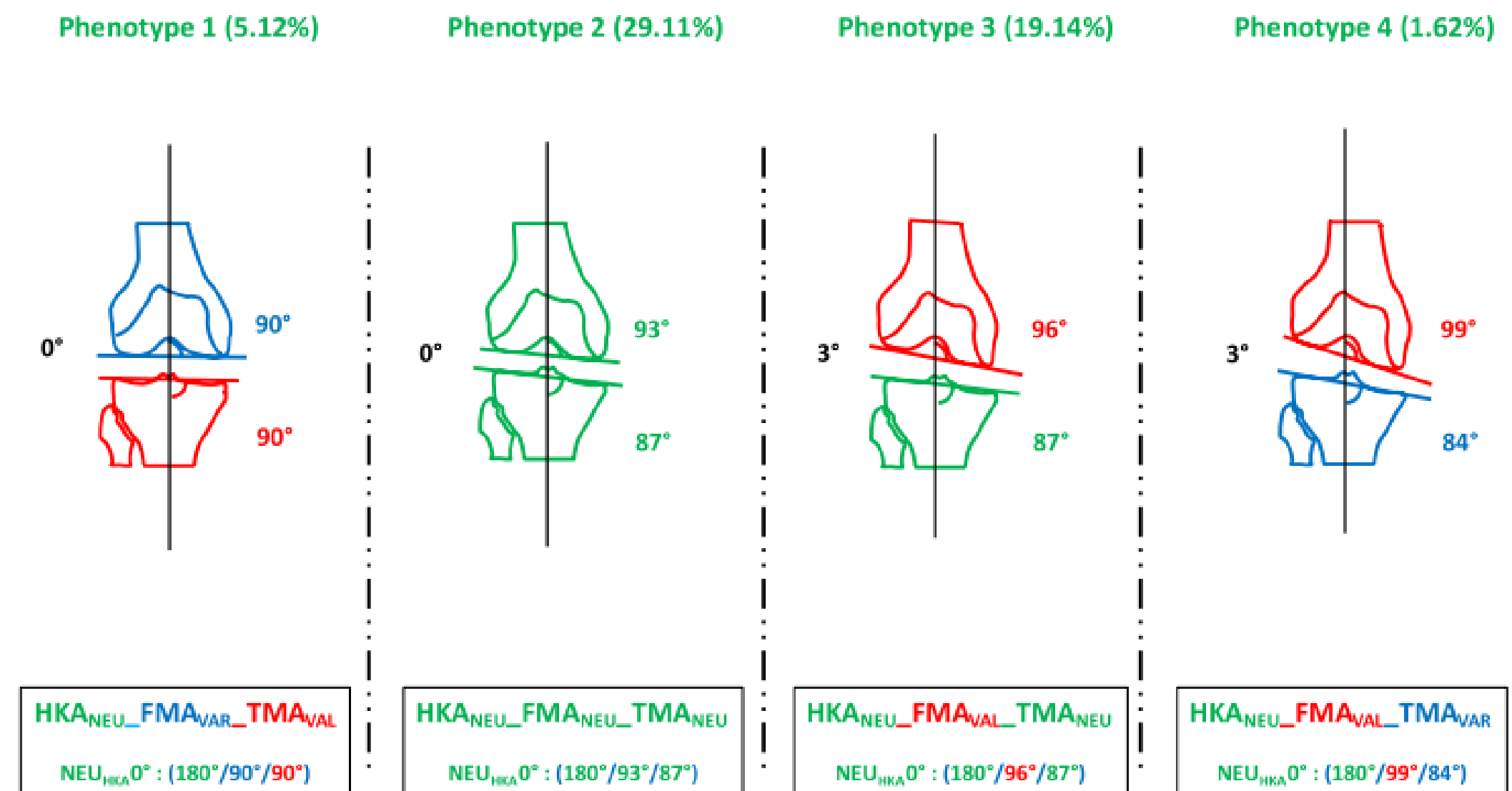
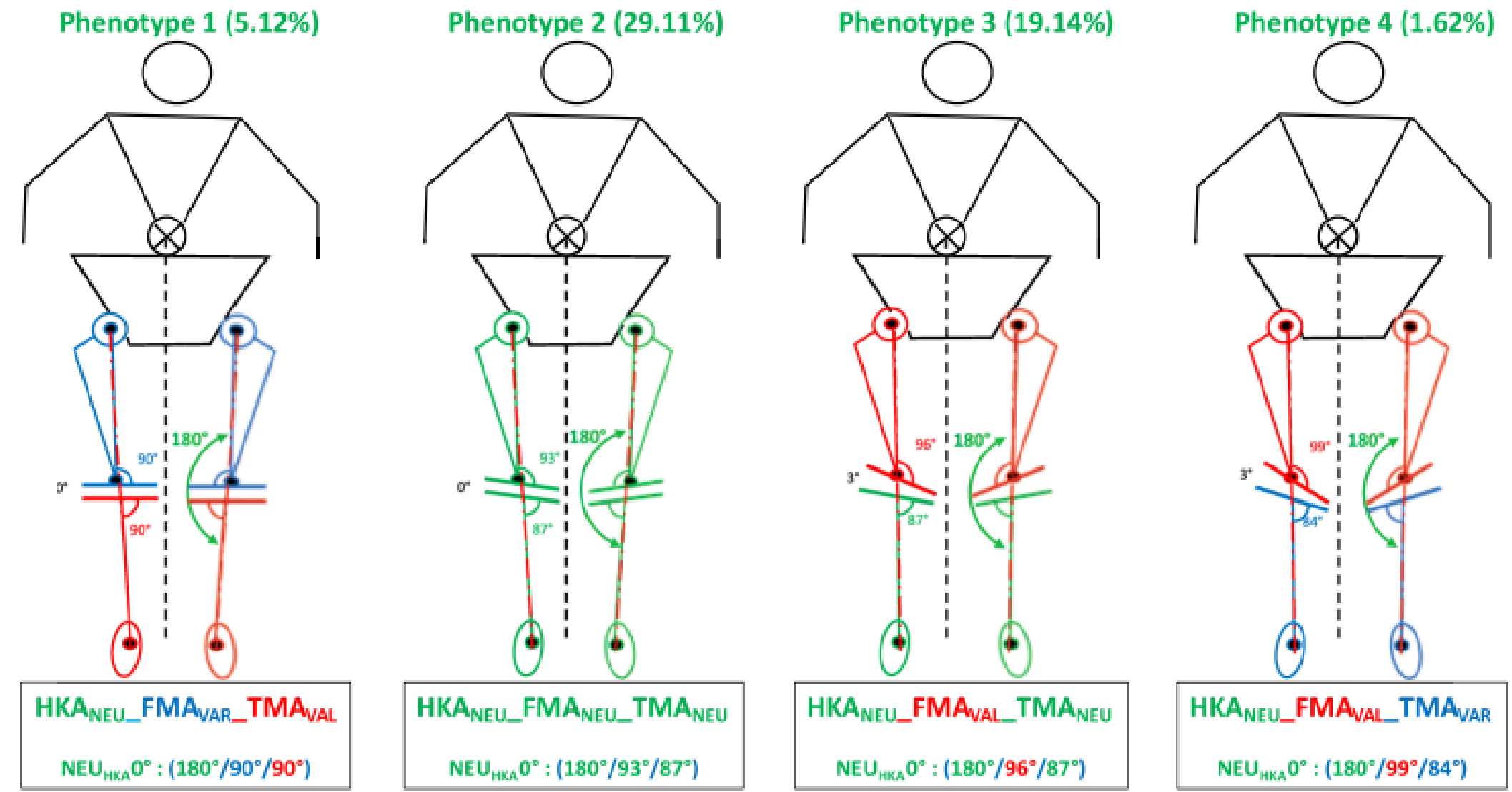
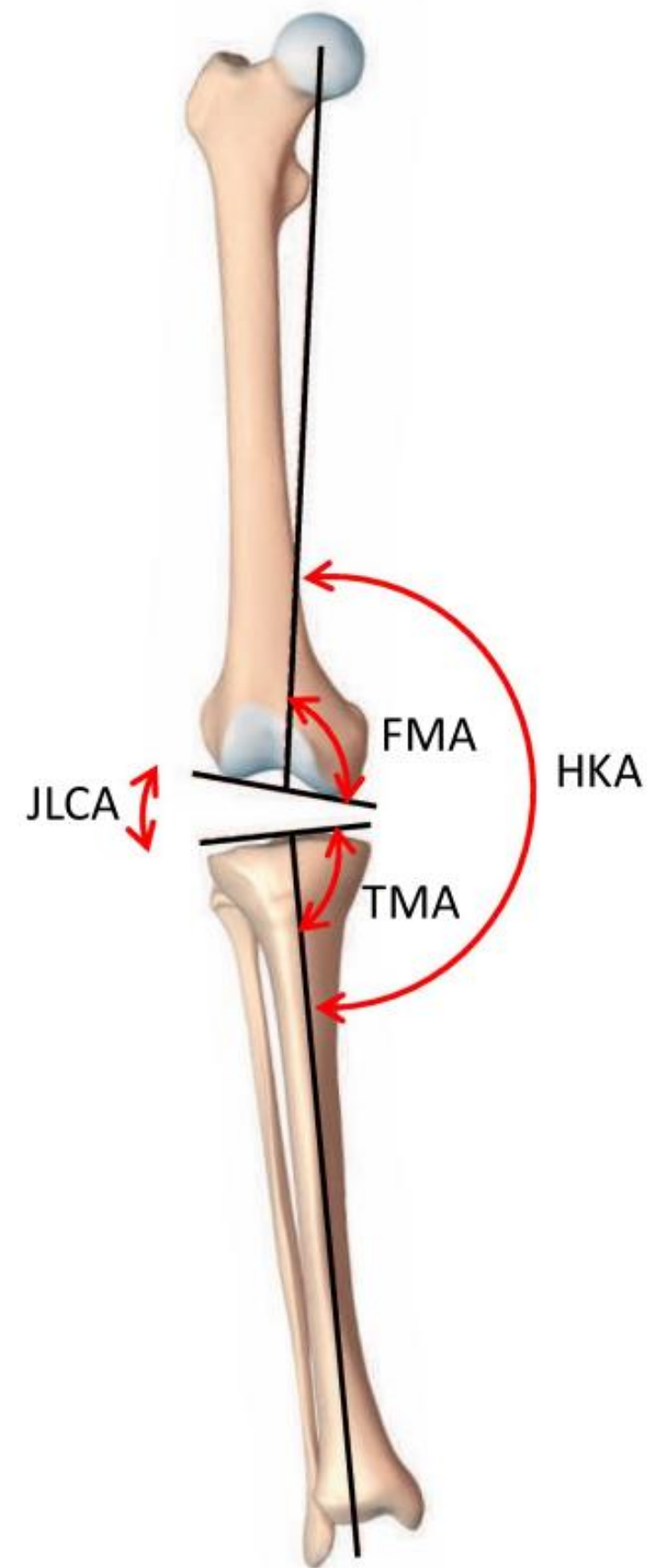
NORMAL



20-30%

BOWLEGS





Alignement

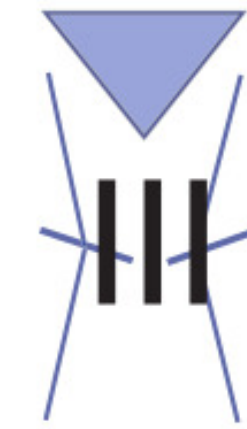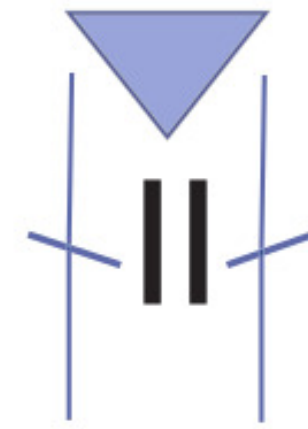
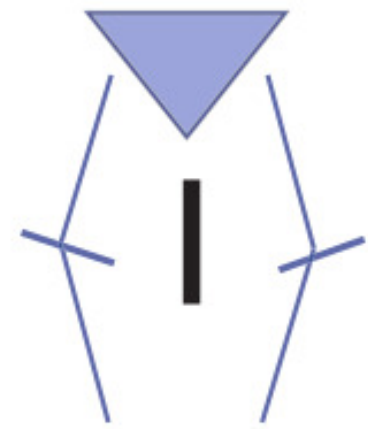
Arithmetic HKA (MPTA - LDFA)

VARUS


NEUTRAL

VALGUS

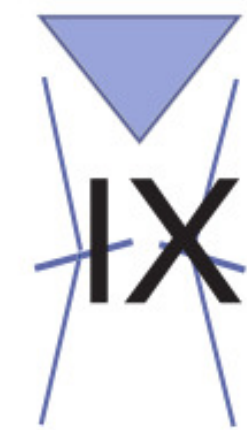APEX DISTAL



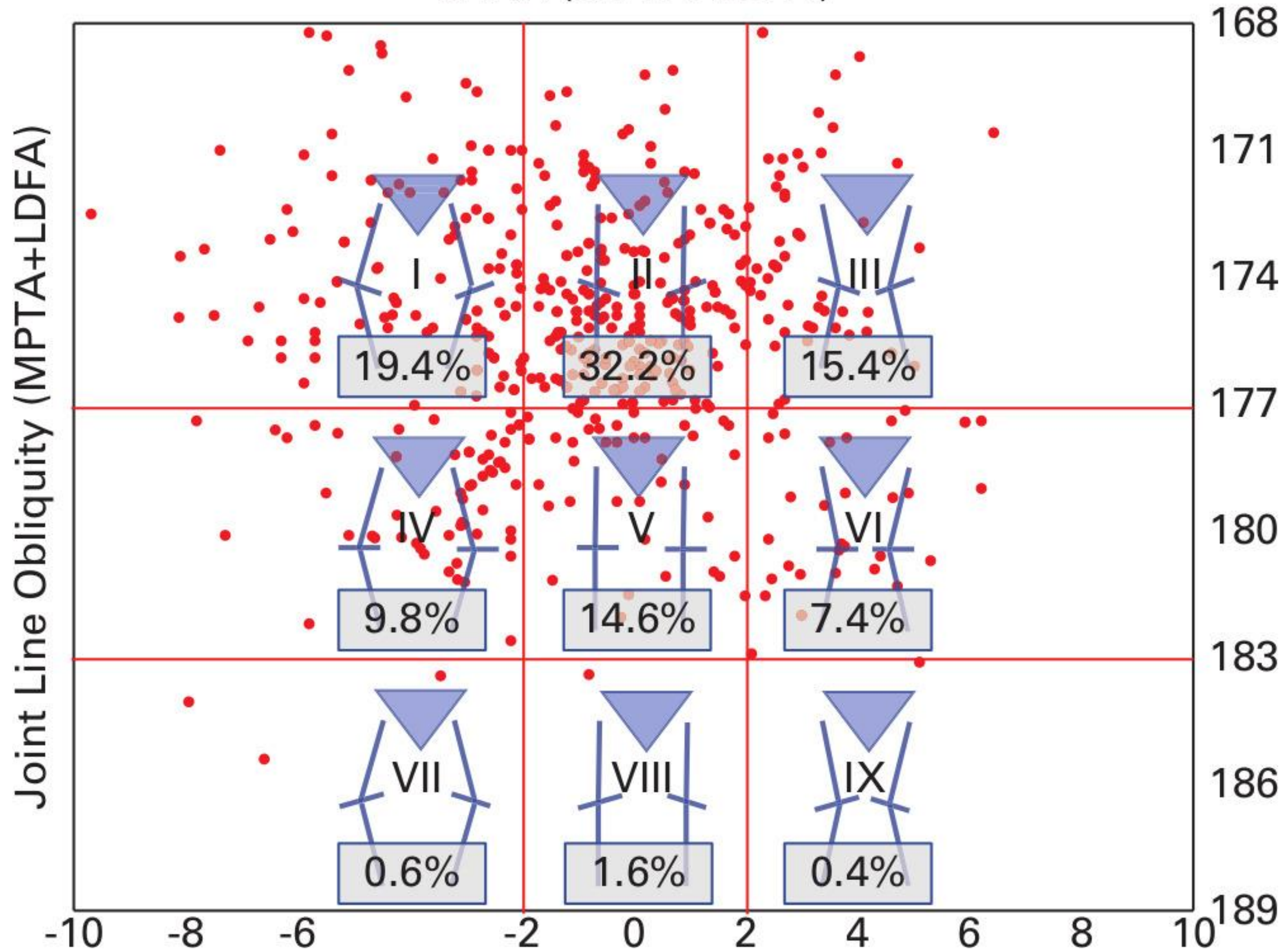
NEUTRAL



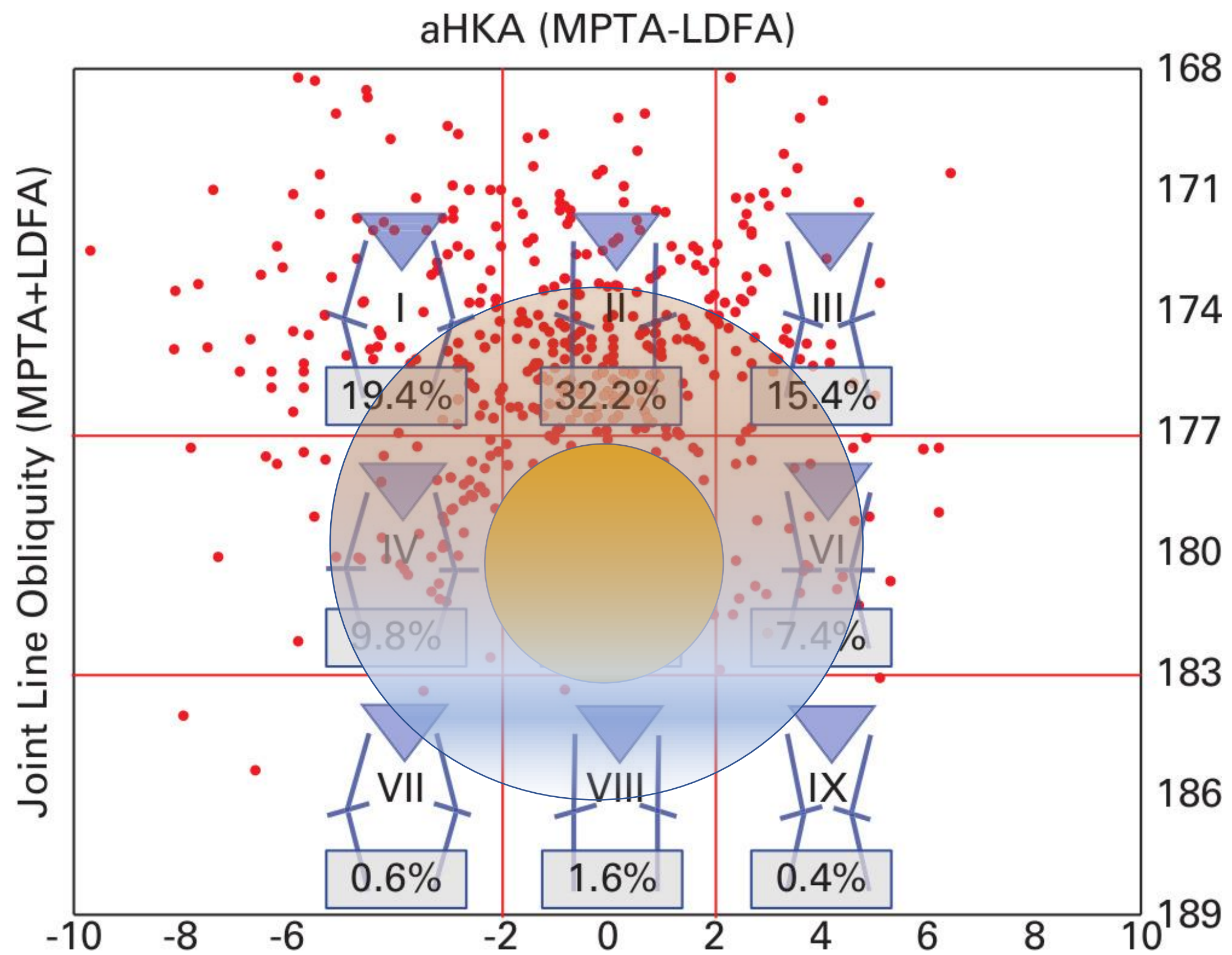
APEX PROXIMAL



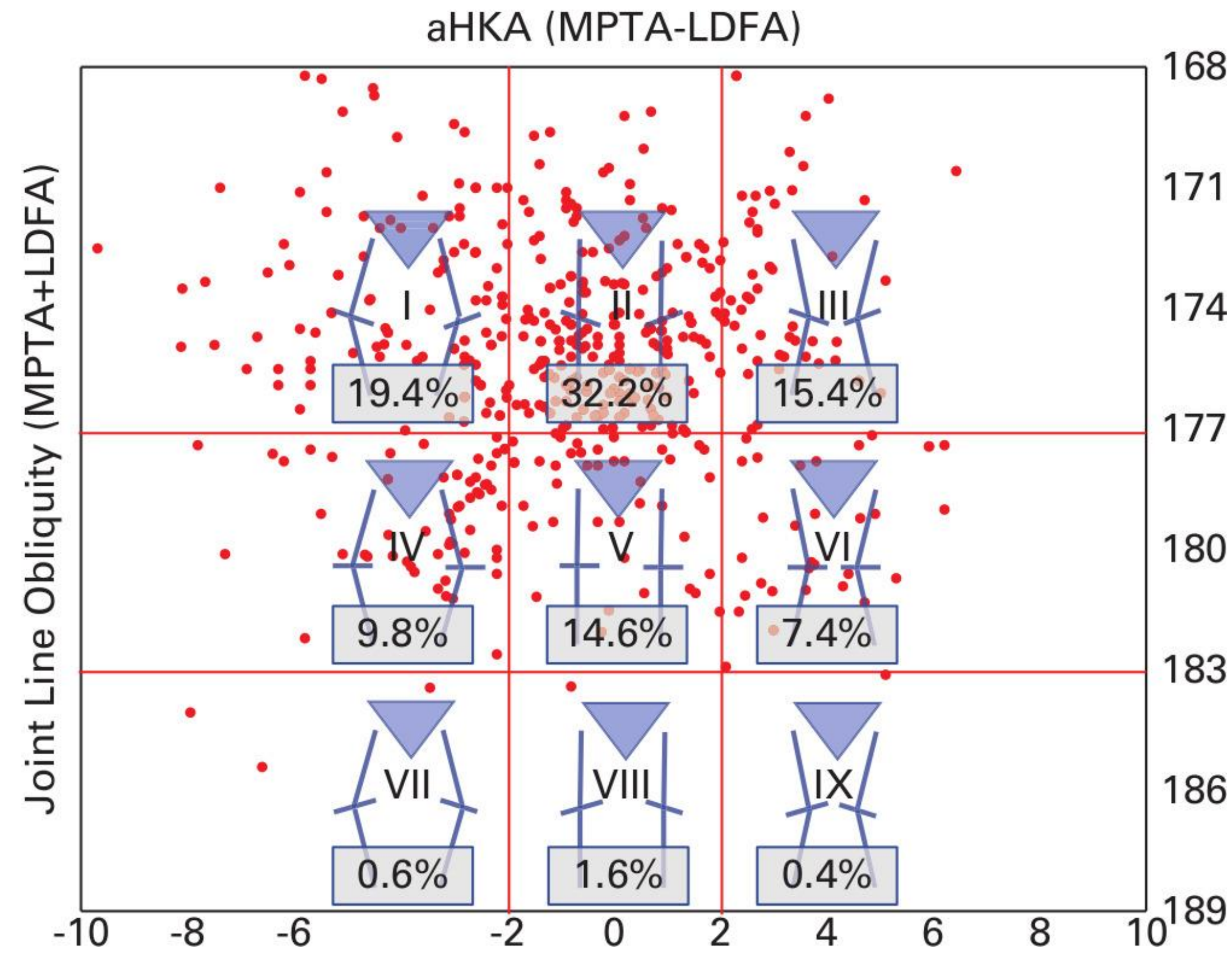
aHKA (MPTA-LDFA)



Conventionele TKP



ROBOT TKP



Anatomische variatie

- Alignement
- **Morfologie**
- Wekedelenenveloppe

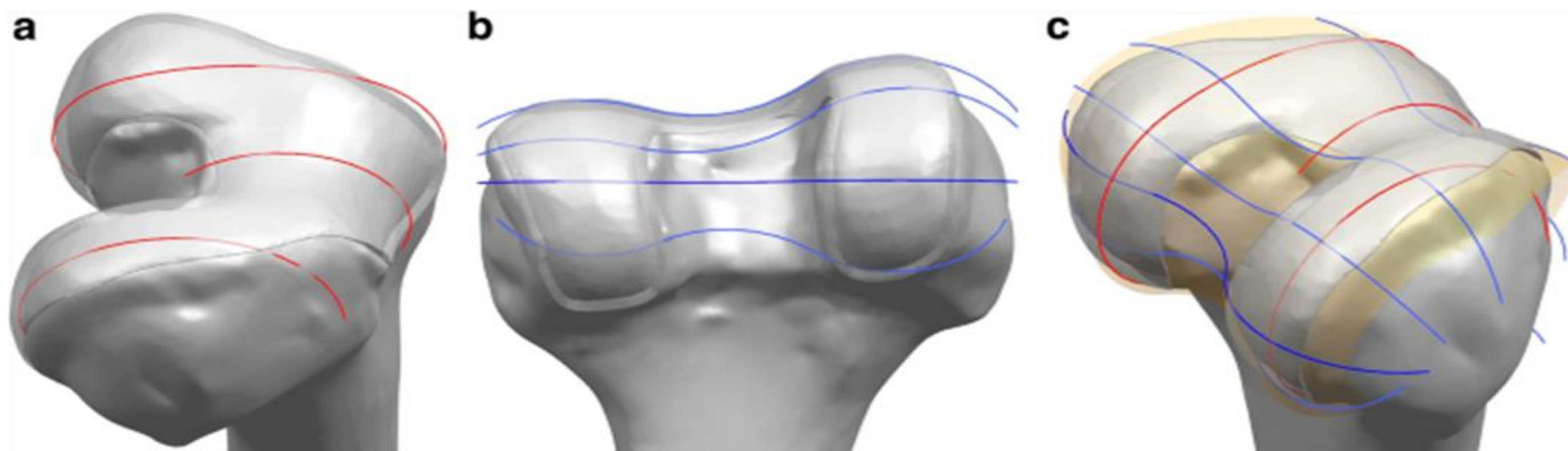
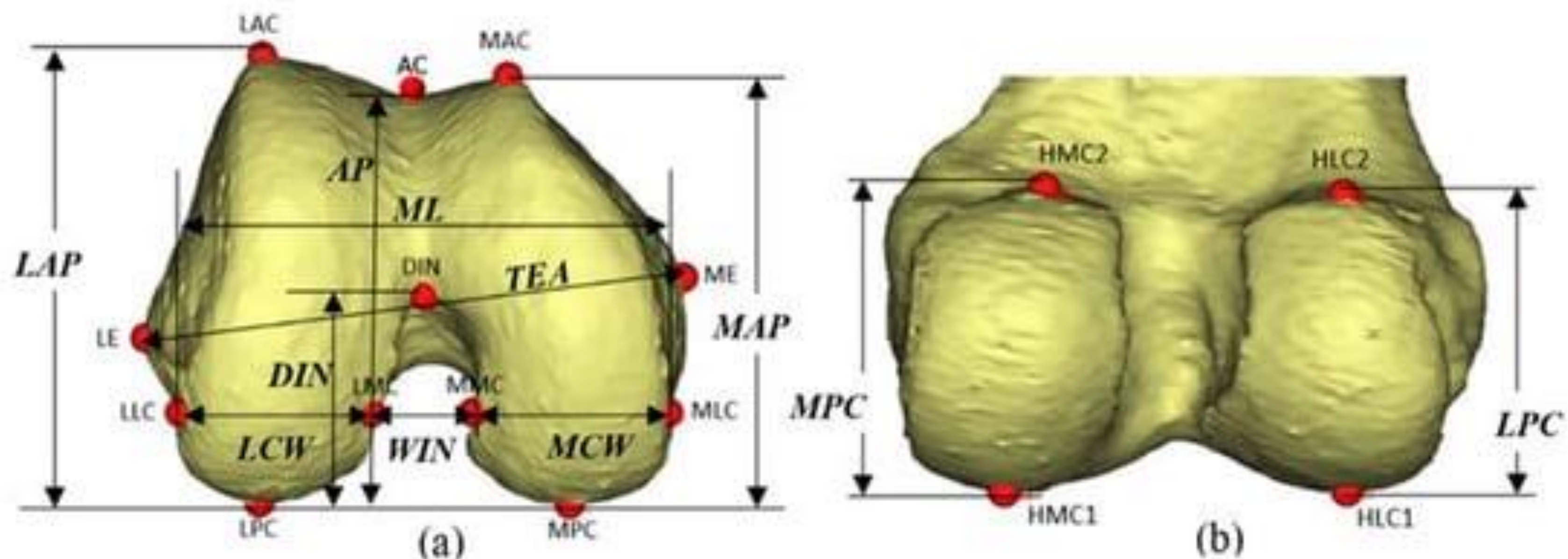


ORTHO.GENT

ORTHOPEDIE & TRAUMATOLOGIE

Variatie in morfologie van de knie

- Tibiale slope
- Saggitale contour
- Trochlea
- Condylaire offset
- Vorm patella
- Breedte condyl
- Assymetrie tibiaplateau



Sagittale contour femur

Archives of Orthopaedic and Trauma Surgery
<https://doi.org/10.1007/s00402-022-04613-z>

KNEE ARTHROPLASTY



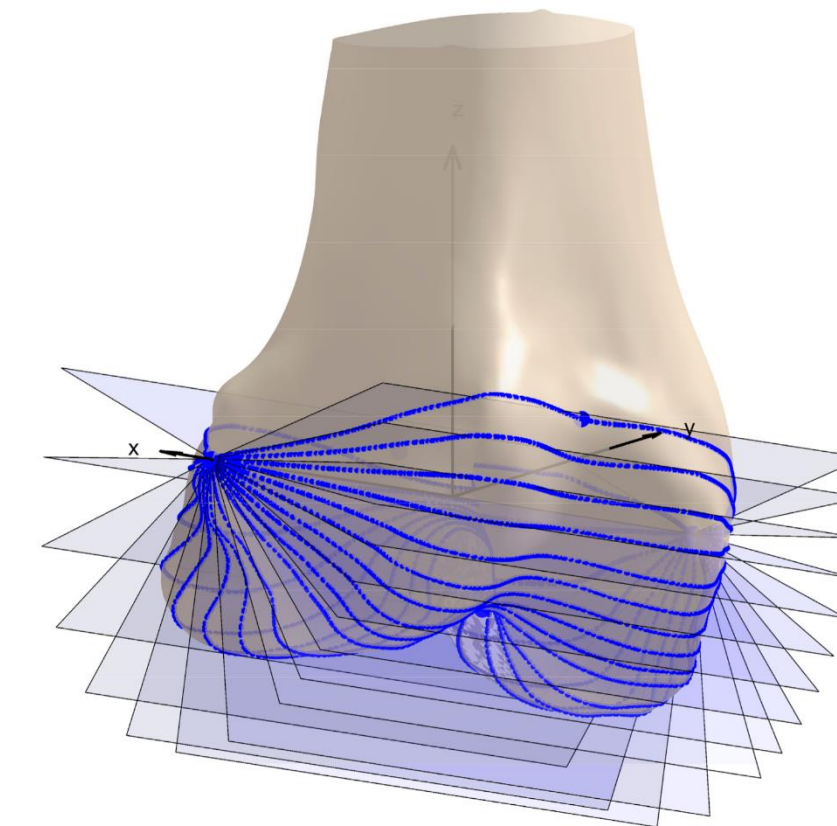
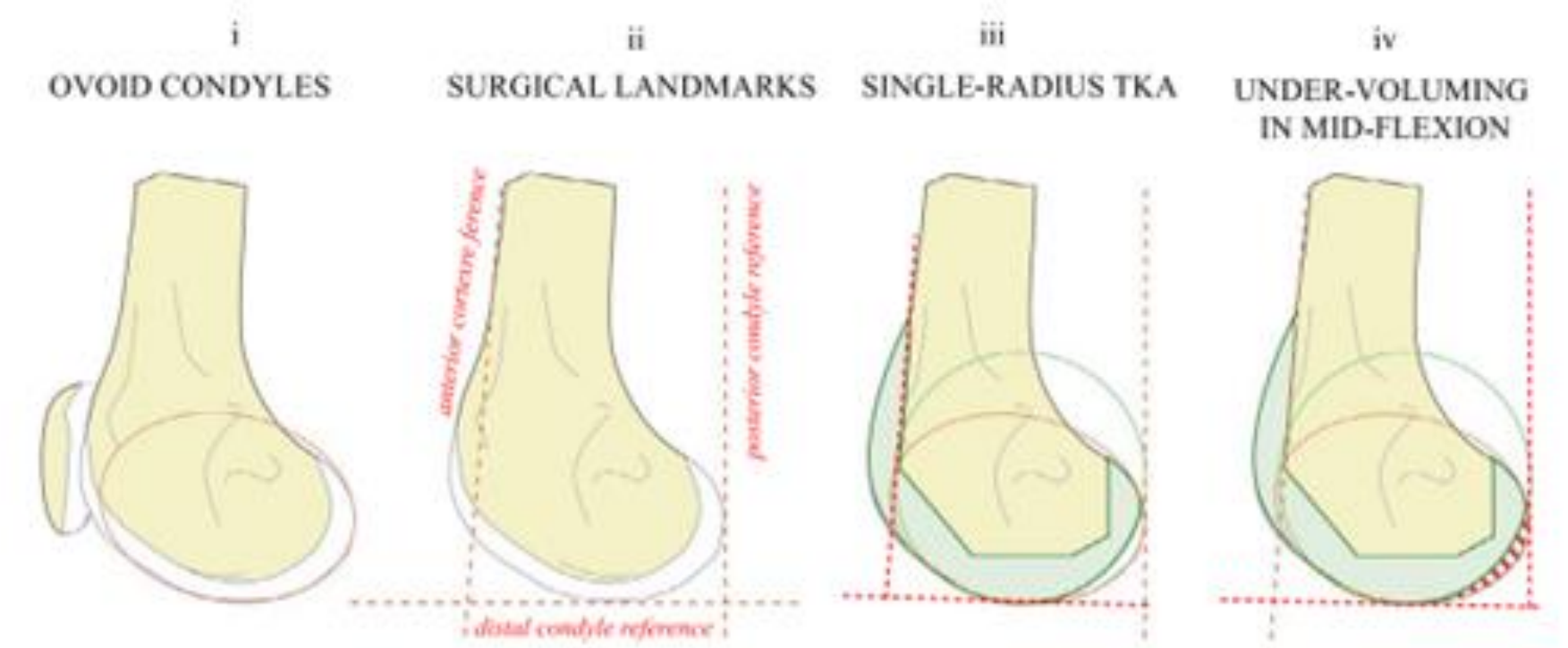
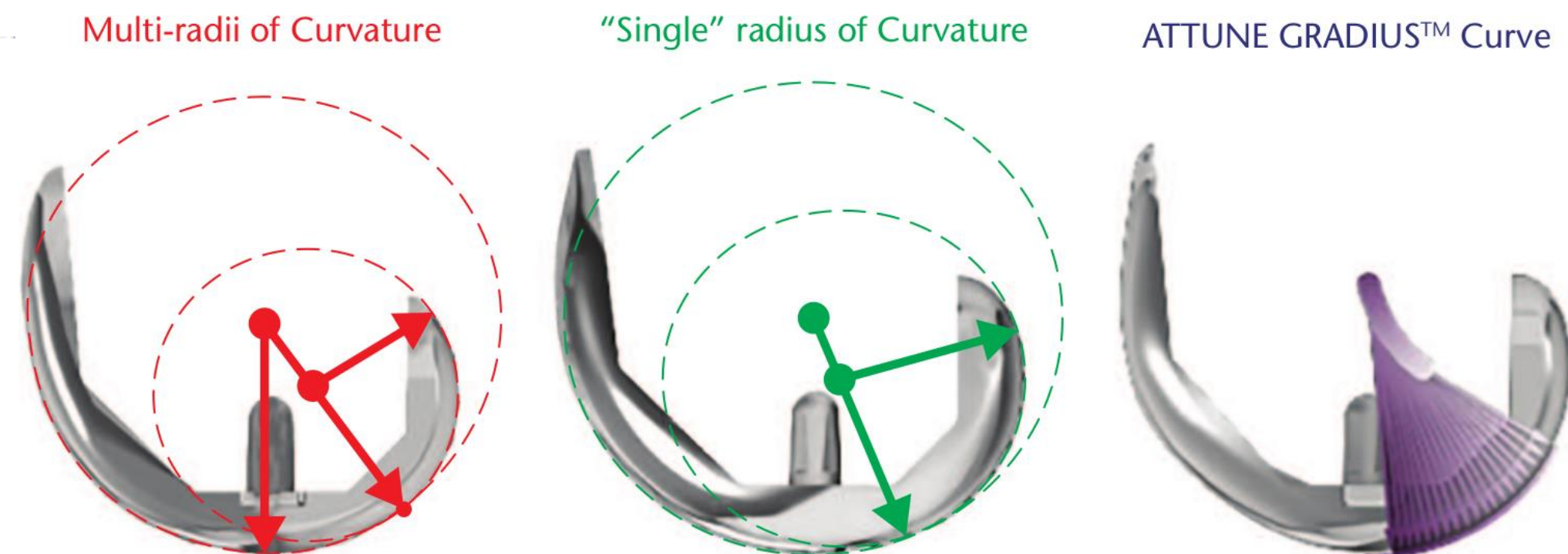
Sagittal femoral condylar shape varies along a continuum from spherical to ovoid: a systematic review and meta-analysis

Andreas Dobbelaere¹ · Jacobus H. Müller² · Tarik Ait-Si-Selmi¹ · Lampros Gousopoulos¹ · Mo Saffarini² · Michel P. Bonnin¹

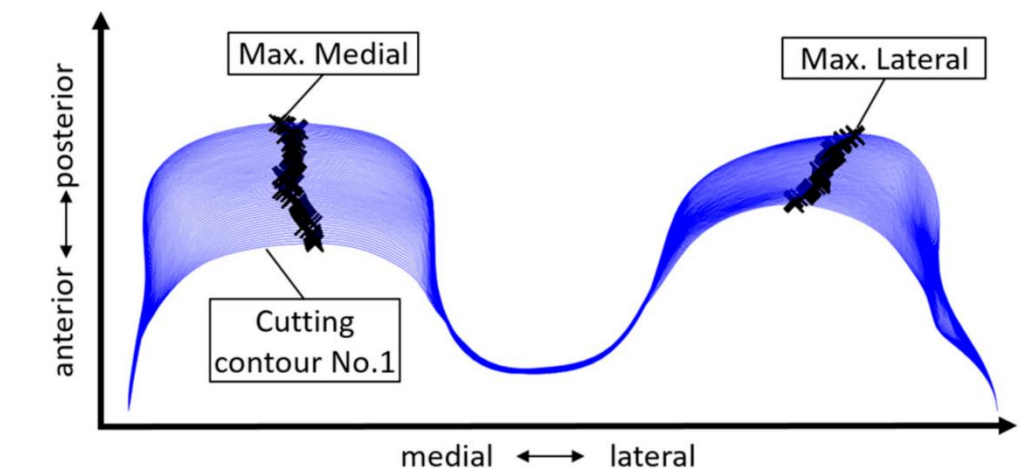
Received: 26 May 2022 / Accepted: 3 September 2022
 © The Author(s), under exclusive licence to Springer-Verlag GmbH Germany, part of Springer Nature 2022

Abstract

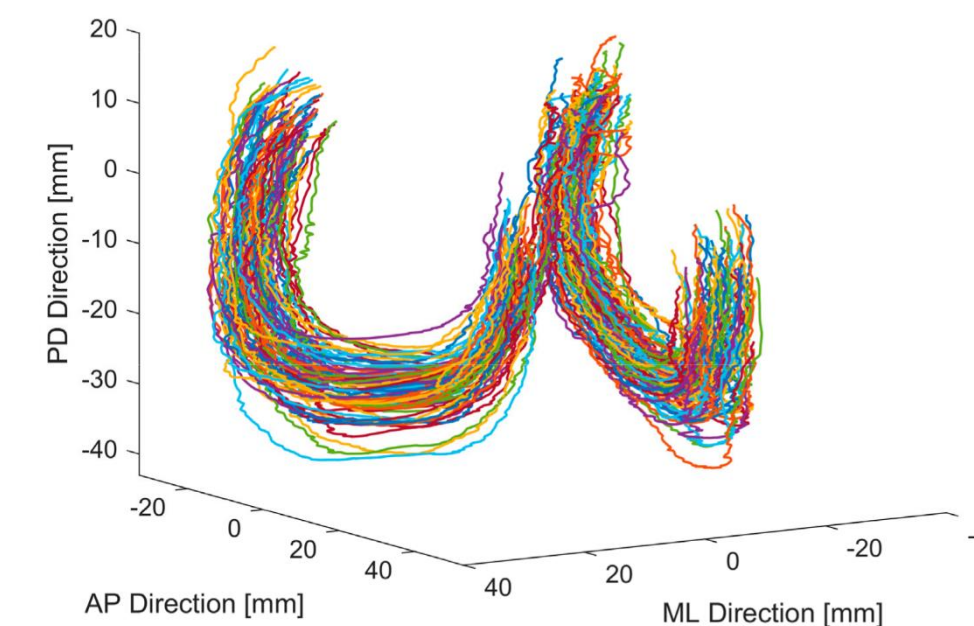
Introduction Considerable anatomic variations of sagittal femoral condylar shape have been reported, with a continuum between **spherical** (or single-radius) and **ovoid** (or multi-radius) condyles. The purpose of this systematic review and meta-analysis was to critically appraise and synthesise the available literature on the sagittal femoral profile. The hypothesis was that studies would reveal considerable variability among individuals, but also in their methodology to quantify sagittal profiles.



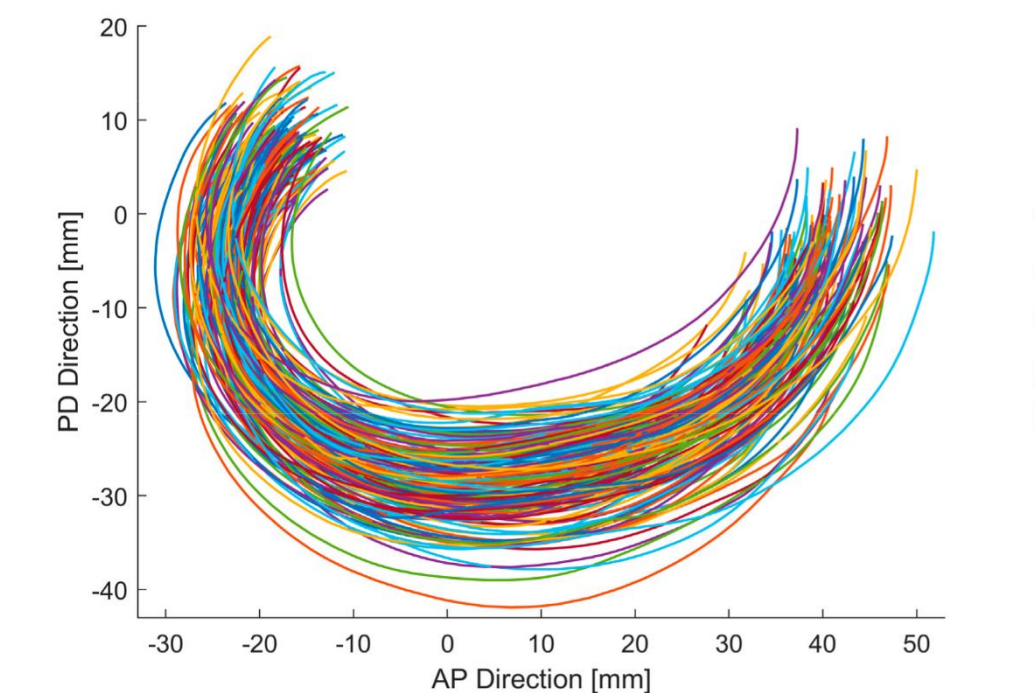
(A)



(B)



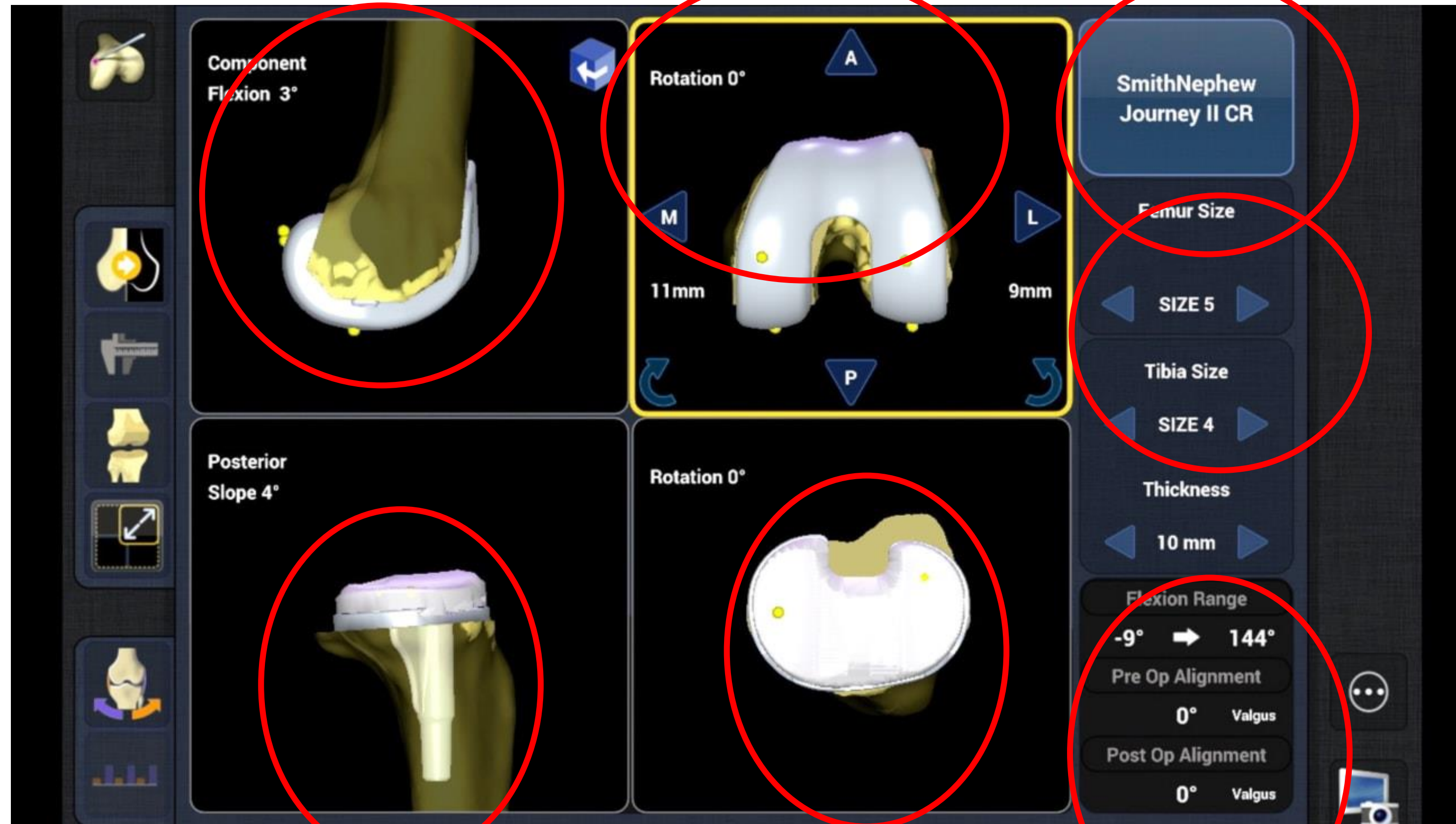(A)



(B)

Positie femur
Sagittale contour

Oriëntatie trochlea



Type prothese

Morfologie:
-grootte tibia
-grootte femur

Tibiale slope

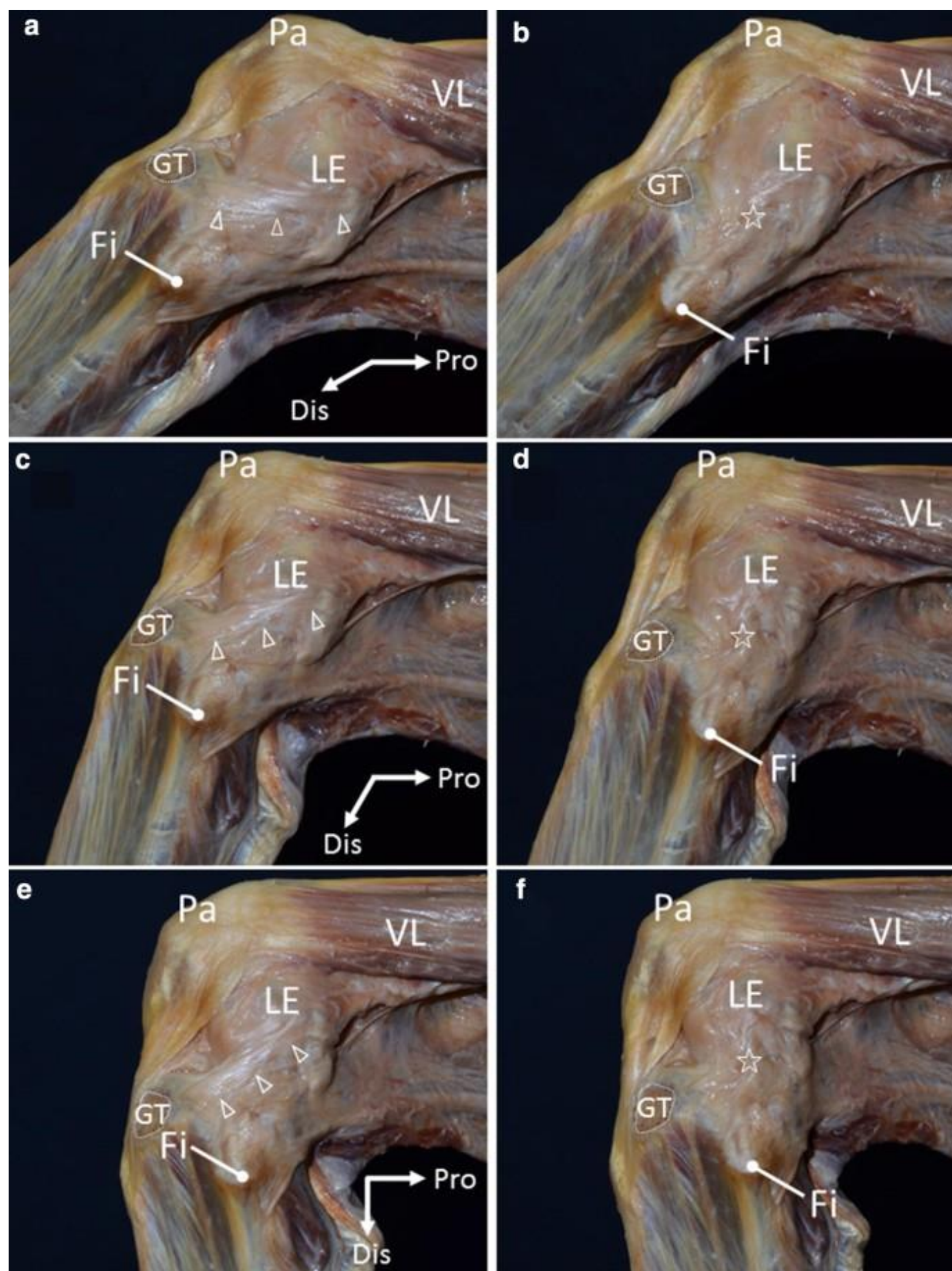
Positie Tibia

Alignement
Range of motion

Anatomische variatie

- Alignement
- Morfologie
- **Wekedelenenveloppe**

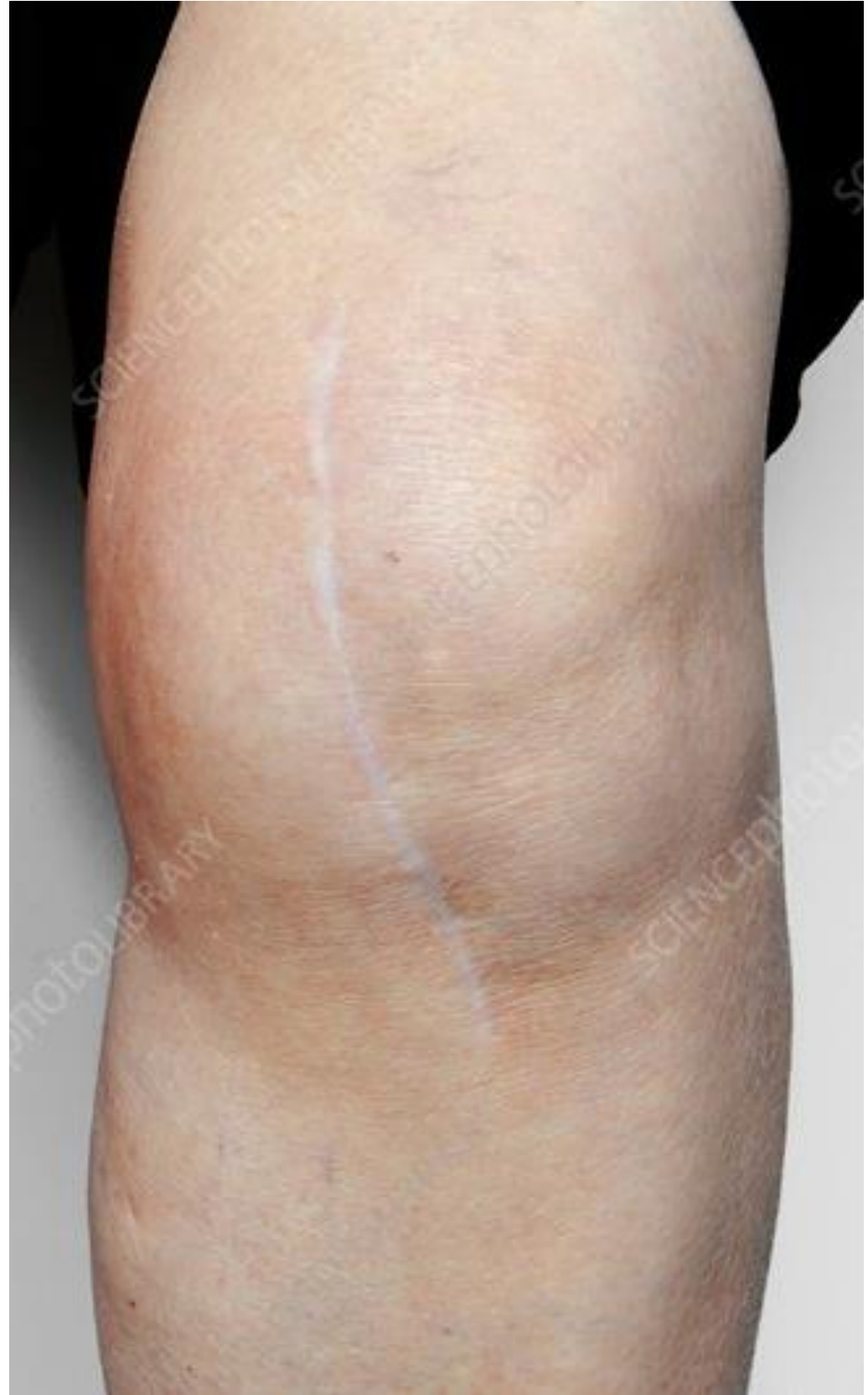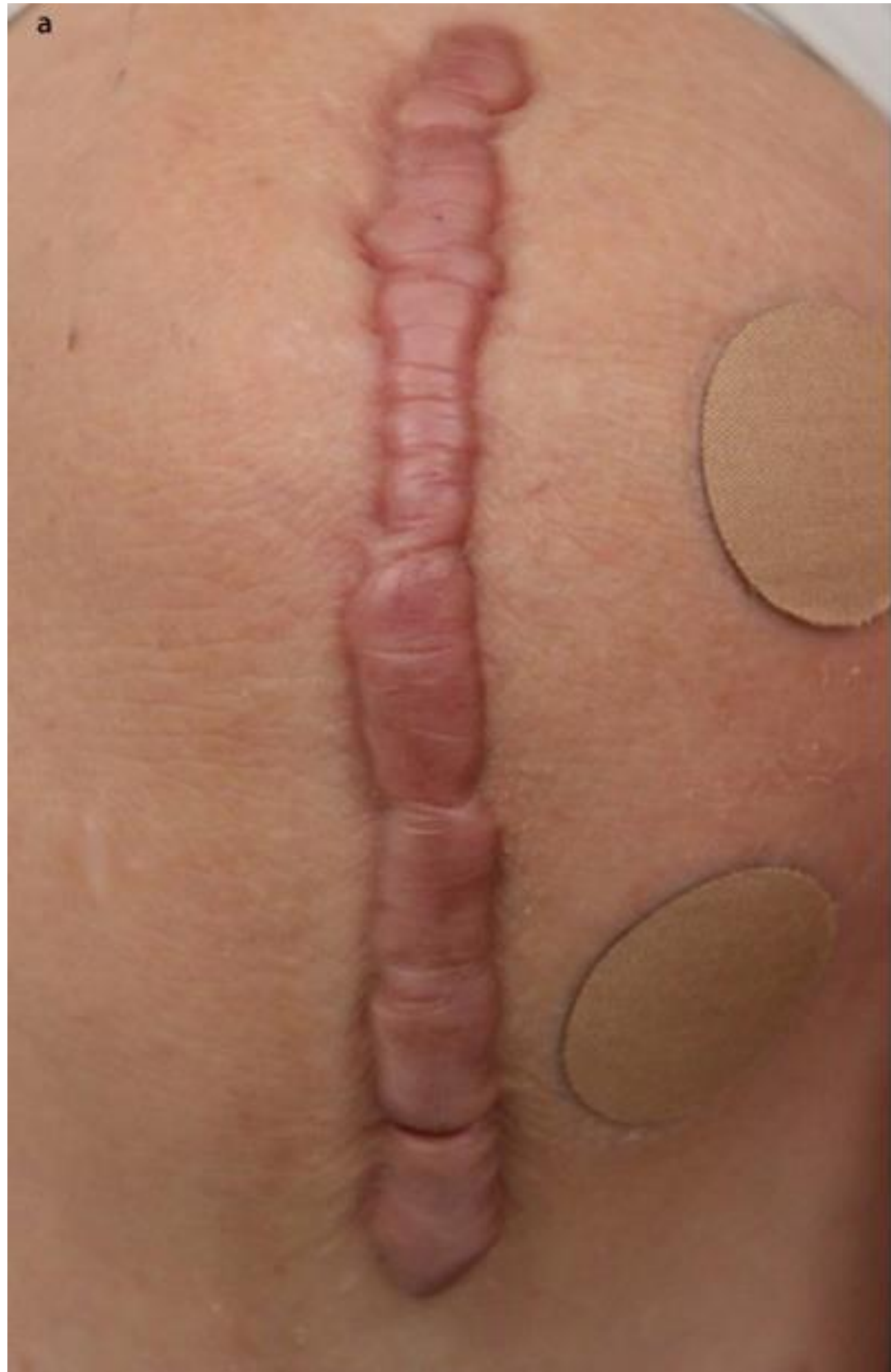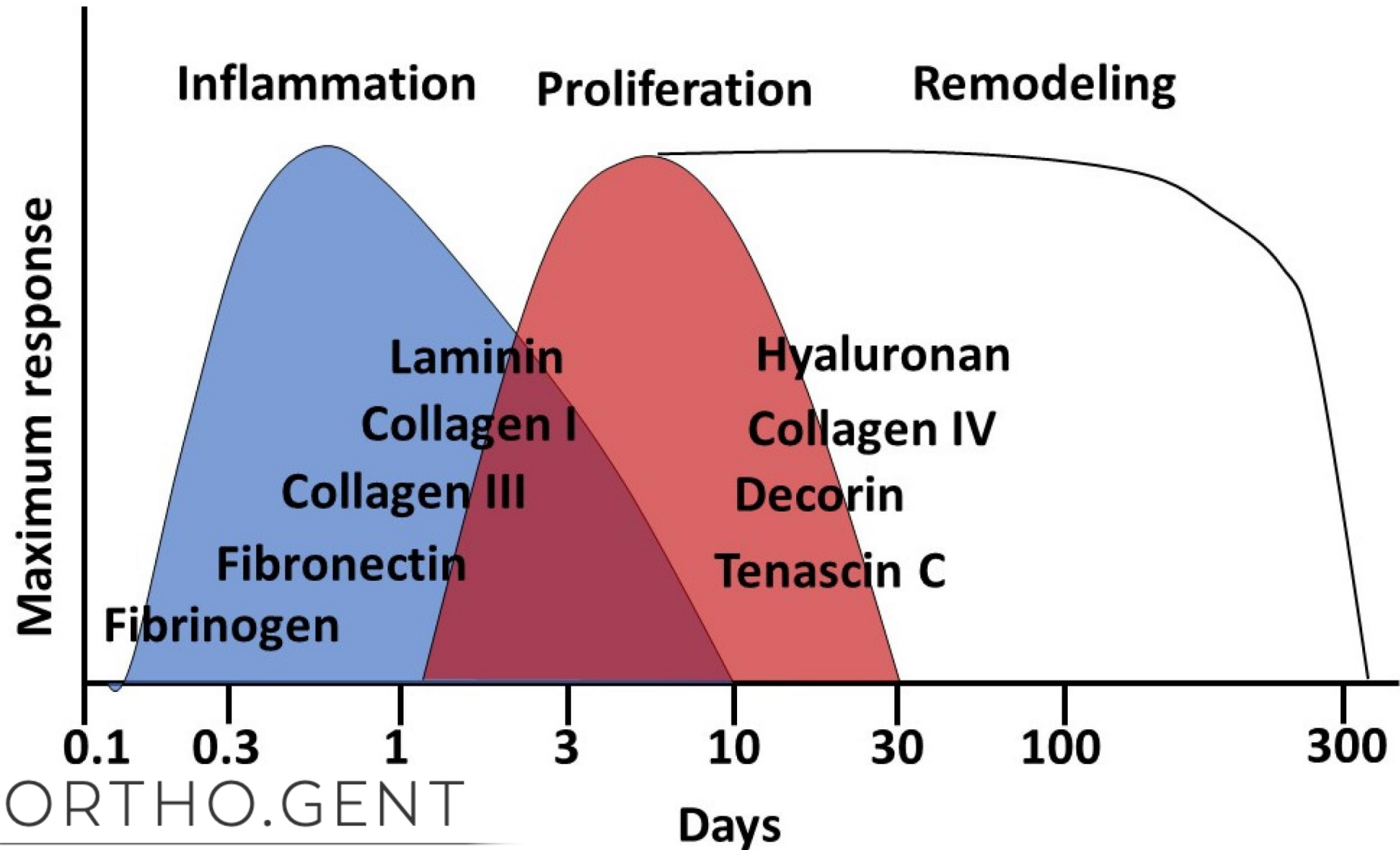
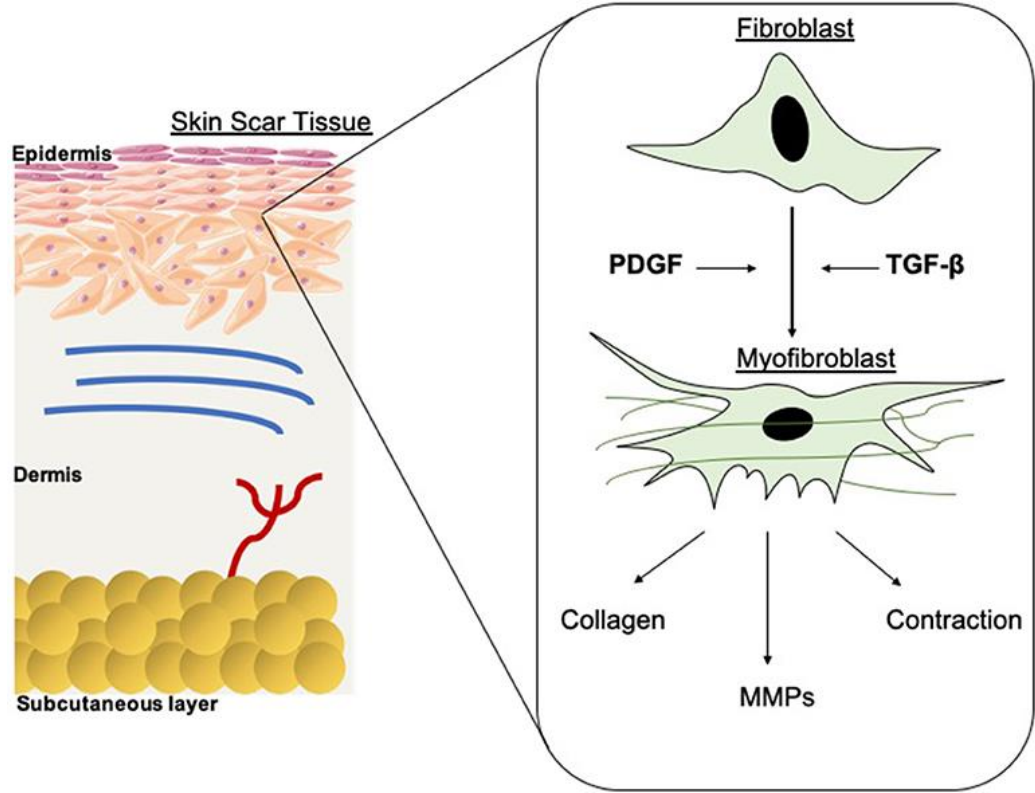
Wekedelenenveloppe: ligamenten



Wekedelenenveloppe: spieren en huid

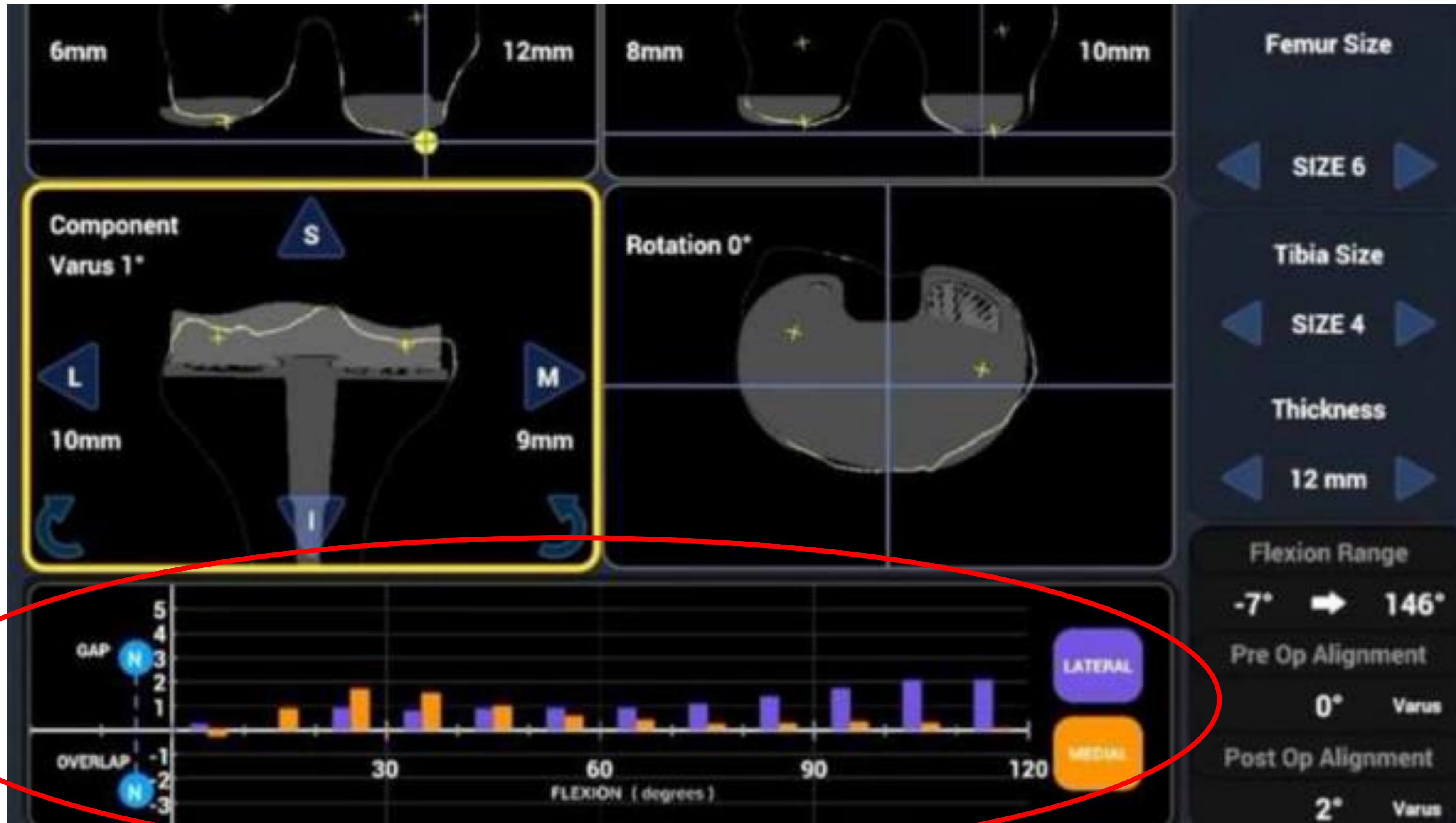

Littekenenvorming



Wekedelenenveloppe

Ligamentaire spanning



Knieprothese

- Unicompartmentele prothese (UKP)
- Totale knieprothese (TKP)
- TKP met ROBOT
- Op maat gemaakte prothese (custom made TKA)

Custom made TKA: Op maat gemaakte knieprothese

Stap 1: CT scan onderbeen voor analyse:

Stap 2: maken van gepersonaliseerd plan

Stap 3: maken van op maat gemaakte prothese

Cas chirurgical

NOM DU PATIENT: **DOE John** DATE DE NAISSANCE: **02.08.1934**

GENOU À OPÉRER: **DROIT** N°ID DU CAS: **109124**

KNEE-PLAN®
ANALYSE PRÉOPÉRATOIRE

MEMBRE INFÉRIEUR

HKS: 6°

HKA: 172°

8° Varus

FLESSUM : 10°

CORONAL

Alpha Dist: 90° Valgus

JLCA: -2° Varus

Beta: 85° Varus

AXIAL

Alpha Post: 95°

SAGITTAL

External Tibial plateau

PPTA: 85°

Slope: 5°

Informations cliniques préopératoires

Alignement en charge:

Extension préop:

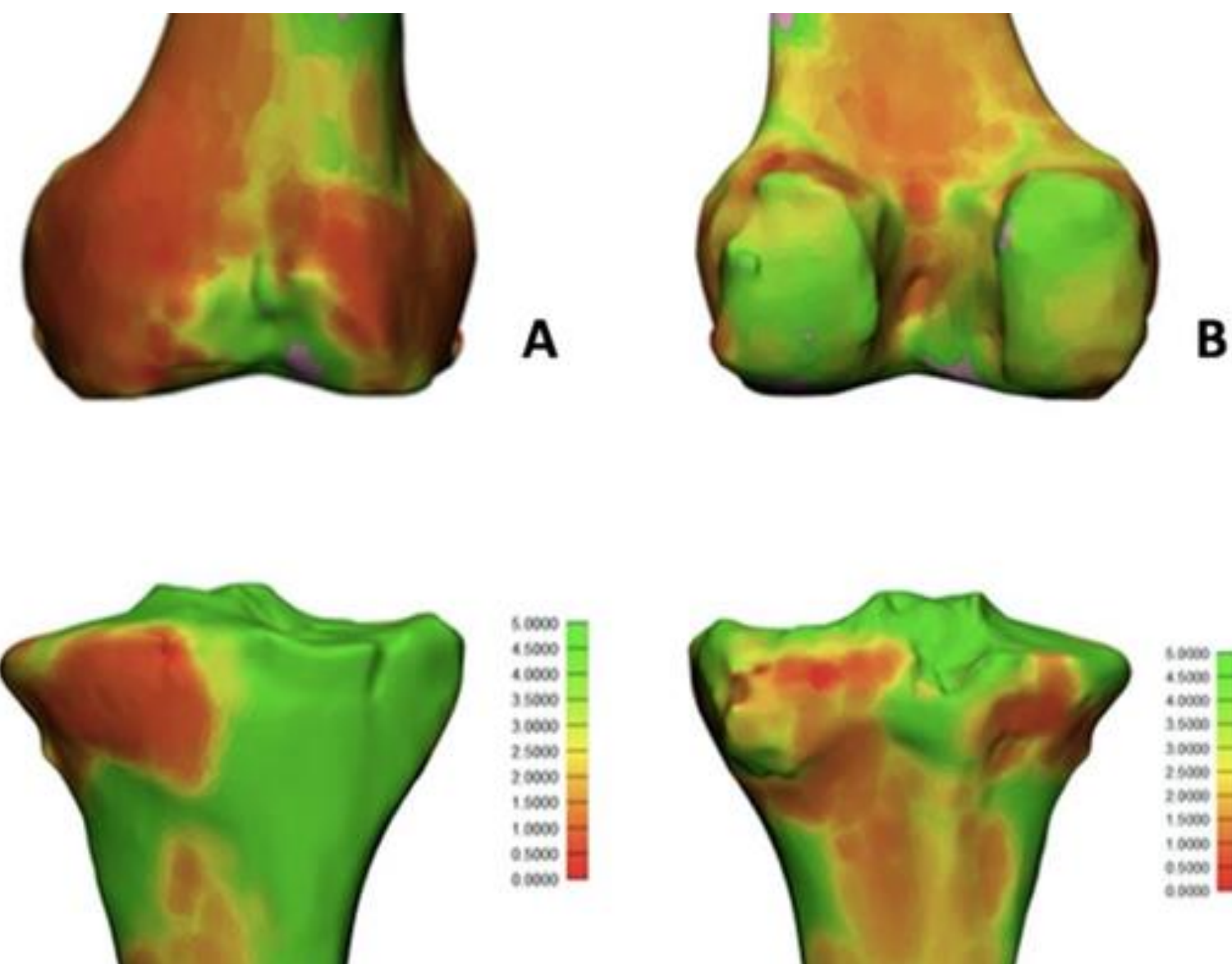
Flexion préop:

Réductibilité:

Commentaires du chirurgien

version 1 30.04.2020 16:14:12
page 1/3

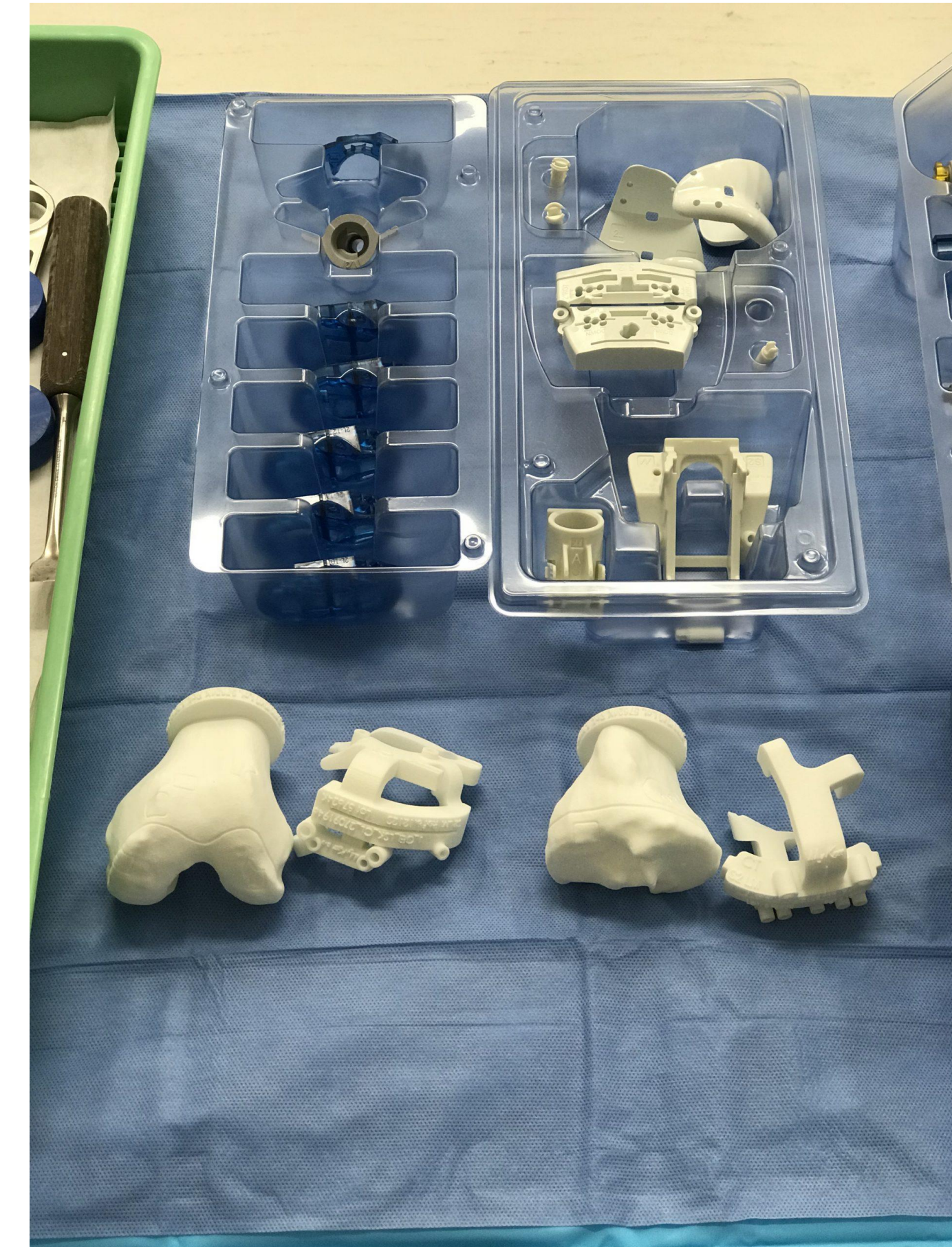
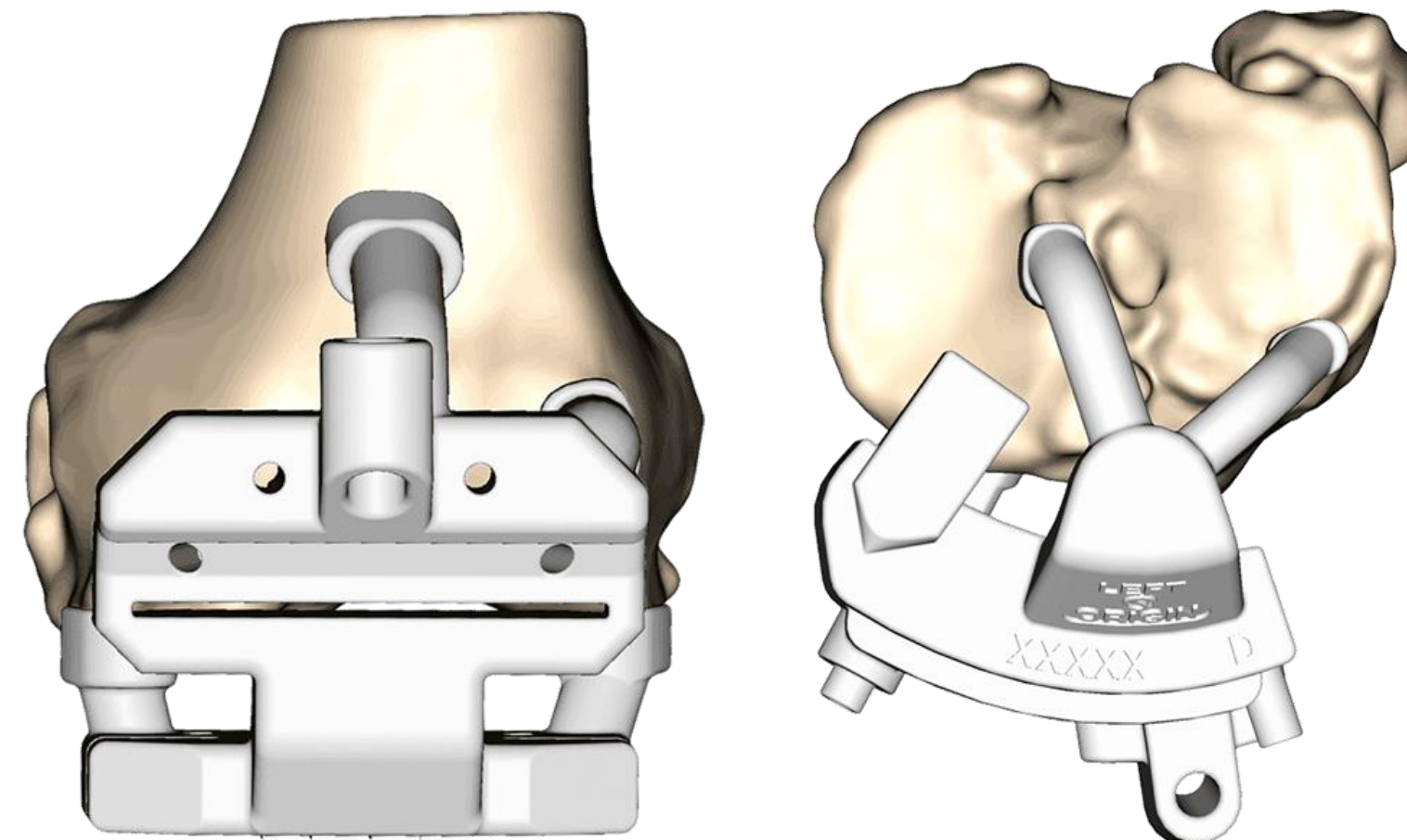
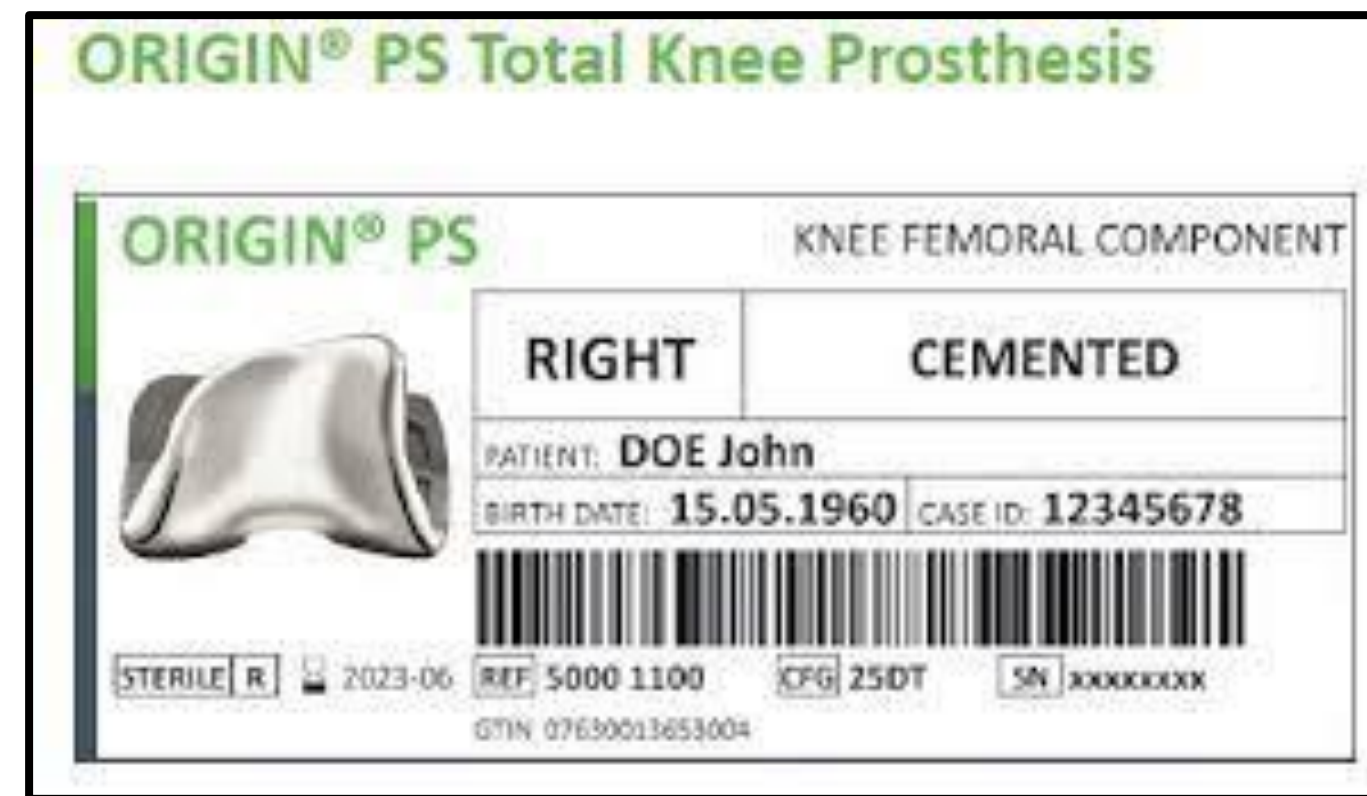
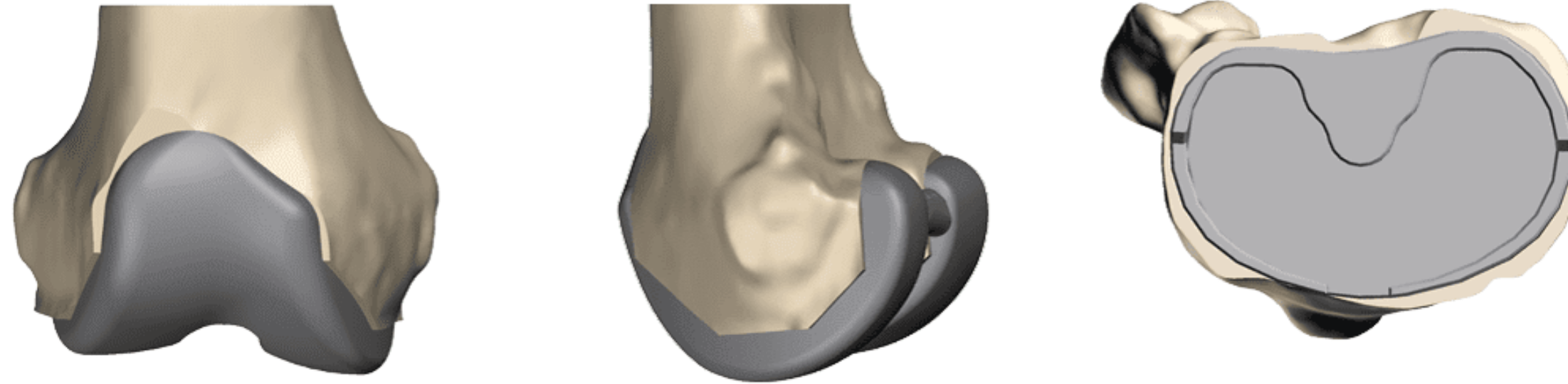
symbios
custom-made for you



Custom made TKA: Op maat gemaakte knieprothese

Stap 4: **Chirurgie:** met 3D geprinte cutting guides

Stap 4: Plaatsen op maat gemaakte prothese





Custom total knee arthroplasty combined with personalised alignment grants 94% patient satisfaction at minimum follow-up of 2 years

Lampros Gousopoulos¹ · **Andreas Dobbelaere¹** · Salvatore Ratano¹ · Louka Bondoux¹ · ReSurg² · Carsten O. Tibesku³ · Tarik Aït-Si-Selmi¹ · Michel P. Bonnin¹

Received: 5 December 2022 / Accepted: 5 January 2023

© The Author(s) under exclusive licence to European Society of Sports Traumatology, Knee Surgery, Arthroscopy (ESSKA) 2023

Abstract

Purpose The purpose was to report detailed patient-reported outcome measures (PROMs) and satisfaction rates for computed tomography (CT)-based custom TKA at minimum follow-up of 2 years. The hypothesis was that custom TKA combined with ‘personalised alignment’ would yield equivalent or better PROMs compared to values reported in systematic reviews and meta-analyses on off-the-shelf (OTS) TKA.

Methods Of an initial cohort of 150 custom TKAs, four died (unrelated to surgery), one required a revision, and five refused participation, leaving 140 patients for analysis. Patients completed pre- and post-operative PROMs (Oxford Knee Score (OKS), Forgotten Joint Score (FJS), Knee injury and Osteoarthritis Outcome Score (KOOS), Western Ontario and McMaster osteoarthritis index (WOMAC)) as well as overall level of satisfaction. Proportions that attained a patient acceptable symptom state (PASS) were calculated for OKS and FJS. Clinical findings were compared to the average scores reported for PROMs in recent systematic reviews and/or meta-analyses on OTS TKA. Descriptive statistics were used to summarise the clinical findings as means, standard deviations (SD) and ranges, or numbers and percentages.

Results At mean follow-up 33.5 ± 4.5 months, 94% (135/143) were either satisfied or very satisfied. Proportions that achieved PASS were 89% for OKS (120/135), and 85% for FJS (118/139). Median OKS, WOMAC and KOOS Symptoms and Pain scores were all within the 4th quartile of medians reported in systematic reviews and/or meta-analyses.

Conclusions At a minimum follow-up of two years following custom TKA combined with ‘personalised alignment’, 94% of patients were either satisfied or very satisfied, and the PASS criteria were achieved in 89% for OKS and 85% for FJS, all of which compare favourably to published outcomes of OTS TKA. Direct comparisons to the literature may not be appropriate, however, considering the heterogeneity of patient demographics and alignment techniques. Randomised controlled trials

Take home messages:

- **Artrosepatroon** bepaalt grotendeels type prothese (4x Rx-opnames)
- **Halve knieprothese** indien mogelijk
- **Robot** helpt ons met: gepersonaliseerde plaatsing TKP
 - Analyse: morfologie en alignement
 - Monitoring ligamentaire spanning
 - Heel precies uitvoeren operatie
- Bij patiënten met afwijkende morfologie: **Op maat gemaakte TKP**



ORTHO.GENT

ORTHOPEDIE & TRAUMATOLOGIE

MACHINES AND HUMANS:

When Work Together Can Give More
Accurate Results Than Working Alone



hartelijk dank